

Oral Biopsy

Why, When and How

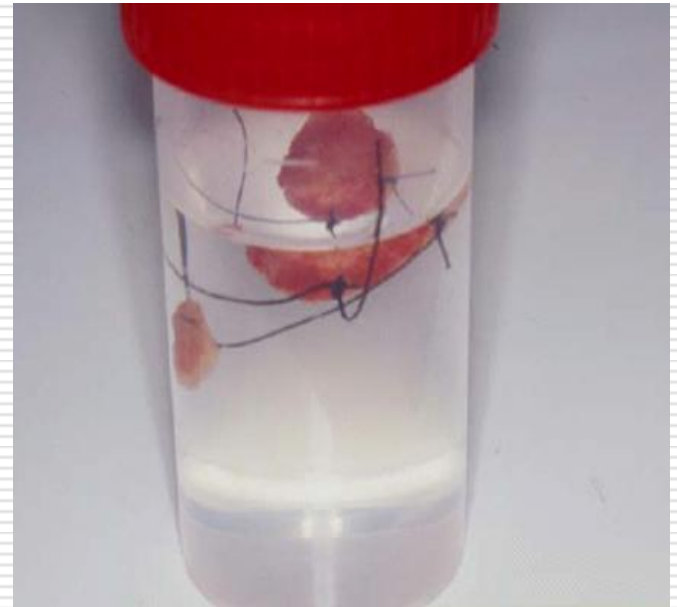Maged Lotfy

Head of OMS Dept, Ain Shams Dental School

Treasure of EAOMS, Project Coordinator

Definition

- Biopsy is a surgical procedure to obtain tissue from living organism for histopathologic examination, usually to perform diagnosis. It is the most diagnostic examination available



Before any biopsy it is the data collected that allows formulation of a differential diagnosis. Looking for a definitive diagnosis is the aim of biopsy

Oral Biopsy ... Why

□ *The aim of biopsy is to :*

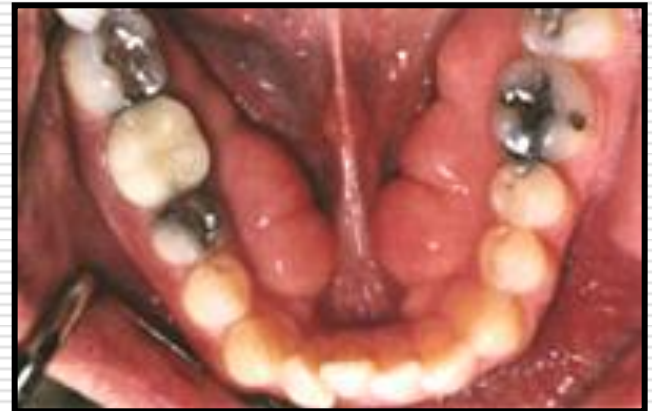- Define a lesion on the basis of its histopathological aspect
 - To establish a prognosis in malignant and premalignant lesions
 - Facilitate the prescription of specific treatment
 - Act as a document with medical-legal value
-

Oral Biopsy ... Why

- For diagnostic confirmation of
 - Suspected **malignant** lesions,
 - **Precancerous** lesions
 - Chronic **ulcerations** of unknown cause
 - Apparently **inflammatory lesions** that do not improve within two weeks of removal of local irritants
-

Oral Biopsy ... When Not Needed

- ❑ Normal structures;
- ❑ Irritative or traumatic lesions that respond to the removal of the local irritant;
- ❑ Inflammatory or infections lesions that respond to specific local treatments
- ❑ Lesions” of long duration with minor clinical change.
 - Torus palatinus and mandibularis



Oral Biopsy ... When Not Needed

- Pulsating lesions (those of vascular nature)
 - Pigmented lesions (melanoma)
 - Cutting through the lesion may initiate malignant transformation
 - **Major salivary glands lesions**
 - Cutting through usually result in salivary fistula
-

Oral Cancer

- ❑ Is the **sixth most common cancer**, accounts for nearly **3.6** percent of all cancers diagnosed
 - ❑ Increase in oral cancer among young adults
 - ❑ Increase in the incidence of tongue cancer cases nearly **5-folds** during the last 30 years
 - ❑ Incidence and survival rate
 - 30,000 new cases diagnosed yearly
 - 8,000 deaths each year
 - 5 year survival rate: 50%
-

Early Detection ... Saves Lives

□ 5-year survival

■ for localized lesions is **76%**

□ 5-year survival

■ for metastatic lesions is **19%**

Dentist Role

The key for reduction of death due to oral cancer is early detection, and **dentist** can play an important role !

- Thorough oral examinations, and detection of the early lesions
 - Biopsy and histological evaluation of the lesion
-

Oral Biopsy ... General Principles

- Before the procedure is undertaken, the characteristics of the lesion should be described in the patient's clinical records together with
 - Possible differential diagnosis.
 - The patient should receive information on the reasons why it is performed.
-

Tissue Examination Methods

□ *Screening*

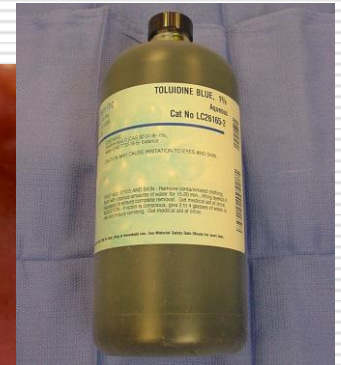
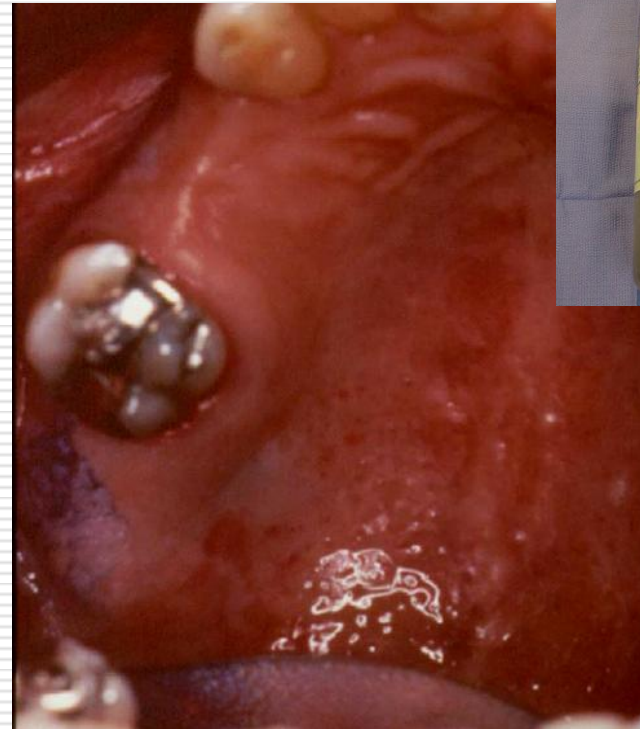
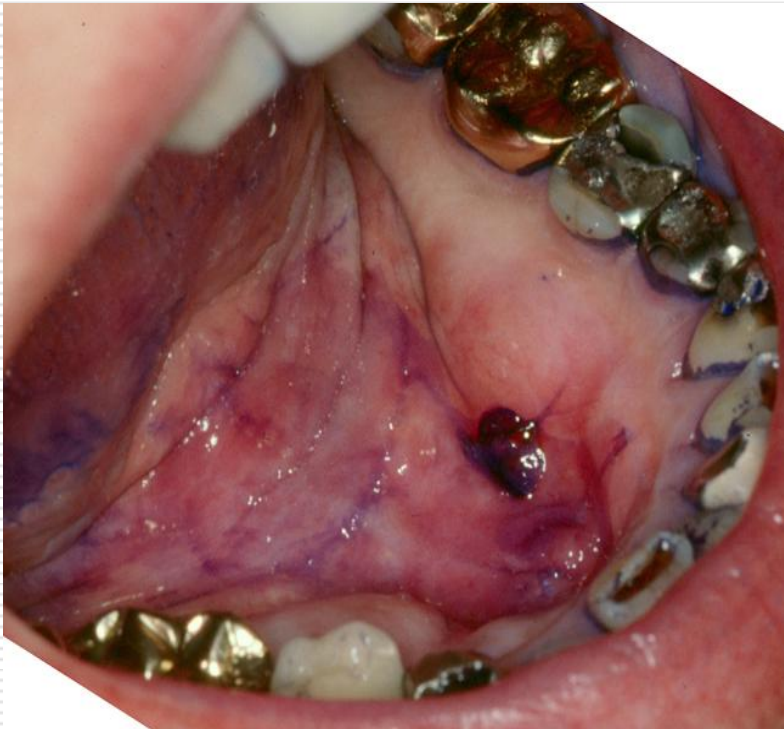- Toluidine Blue
- Oral Brush biopsy
- Exfoliative cytology

□ *Sampling*

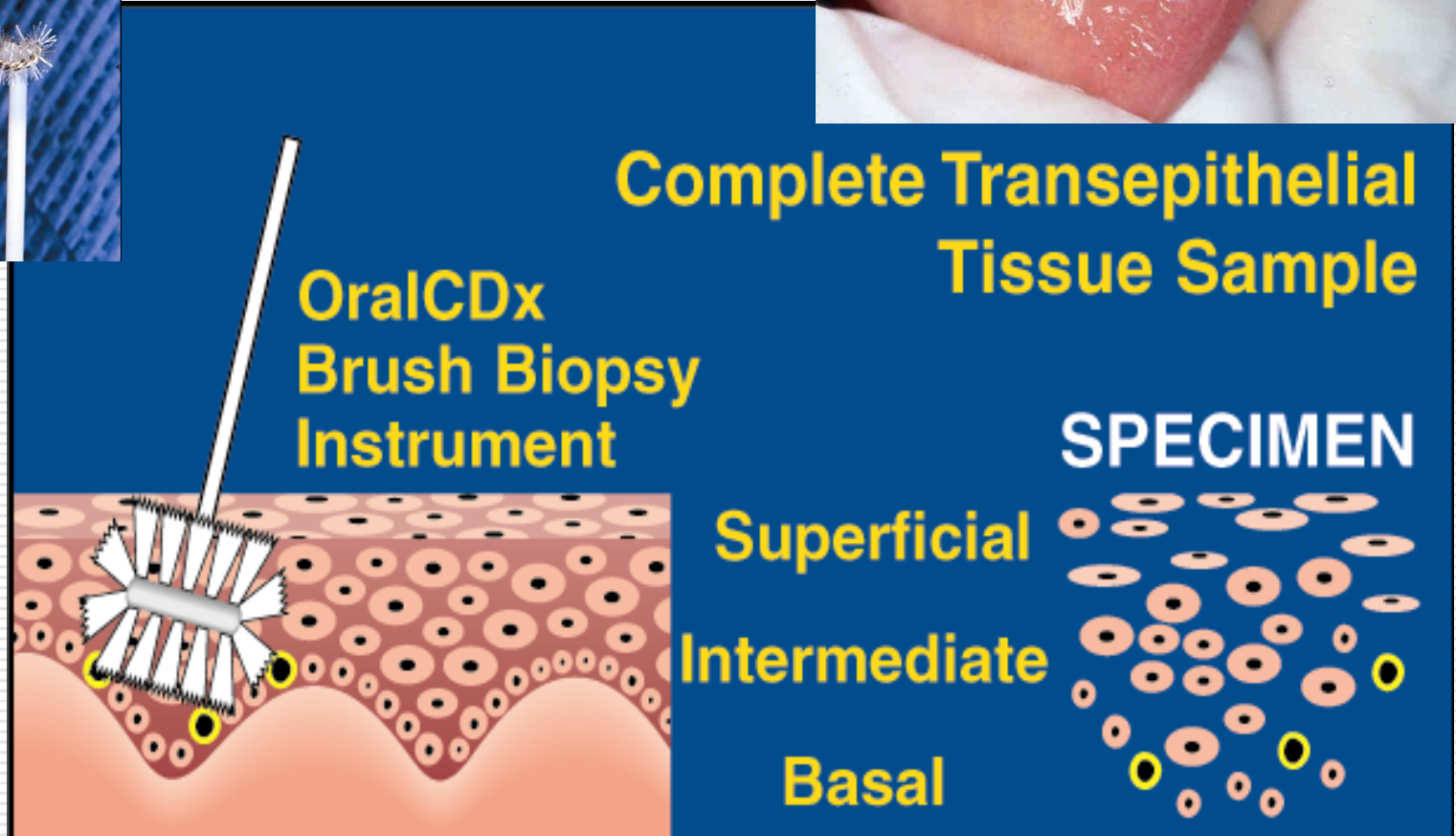
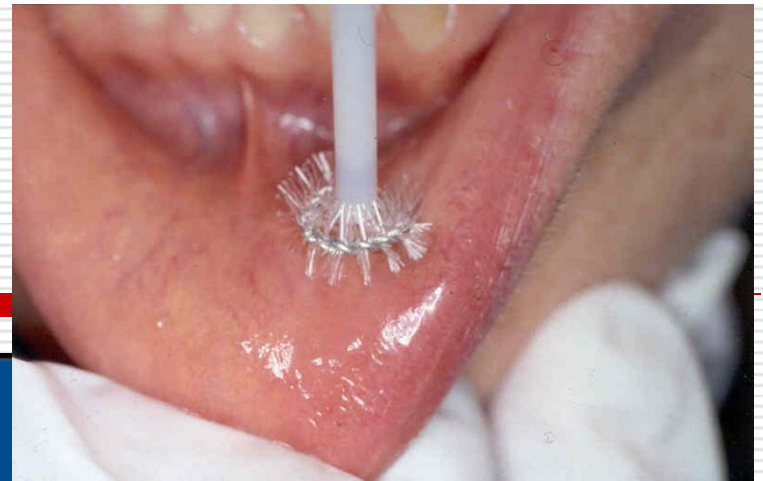
- Fine needle aspiration biopsy
 - Incisional biopsy
 - Excisional biopsy
 - Drill biopsy
 - Frozen sections
-

Toluidine Blue

- *Displays affinity for areas of dysplasia, malignancy and high cell turn over*



Brush Biopsy



Brush Biopsy

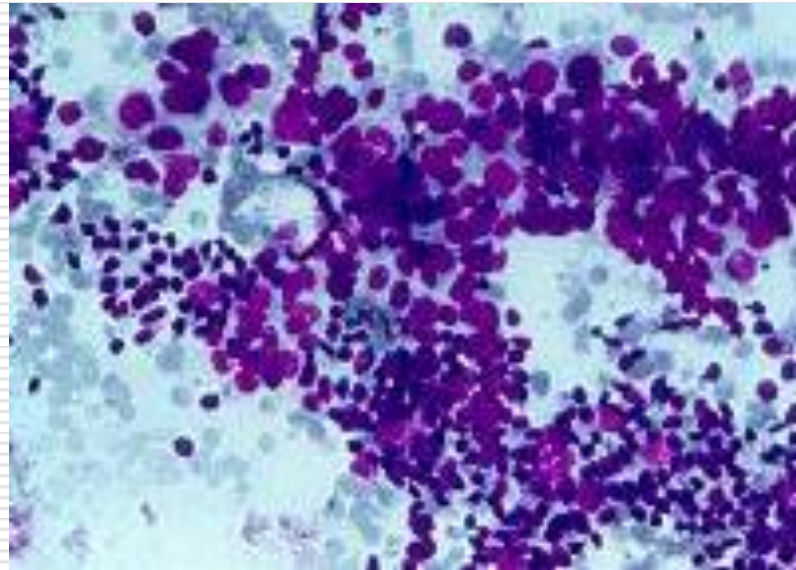
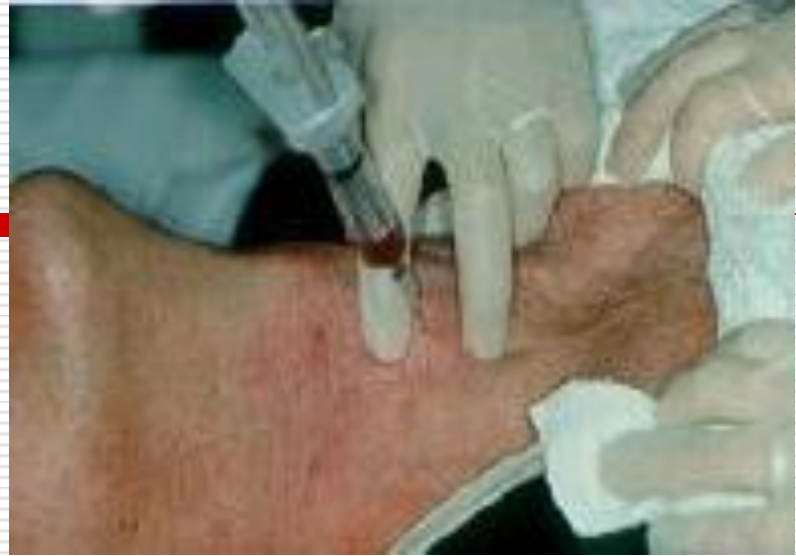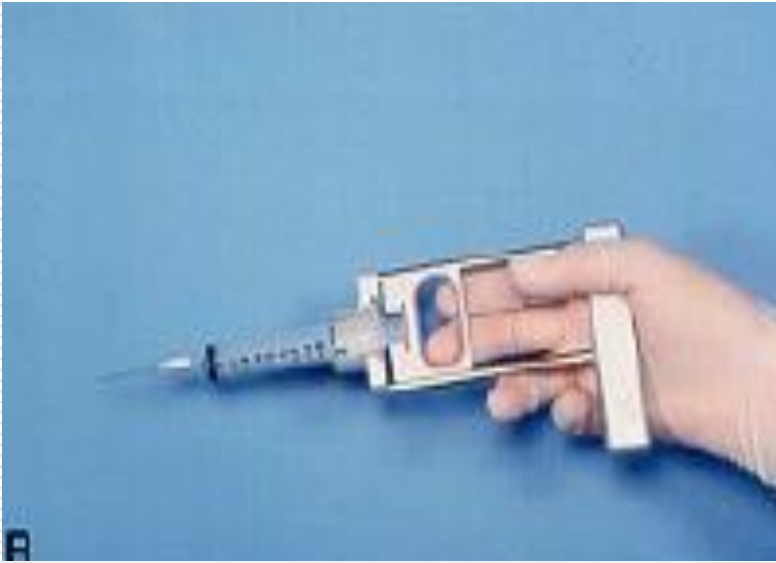- ❑ Think of this technique as a screening tool
 - ❑ This kit helps you decide which lesions need to undergo conventional biopsy
 - ❑ If a lesion is highly suspicious, skip this option and go right to the incisional/excisional biopsy
-

Exfoliative Cytology

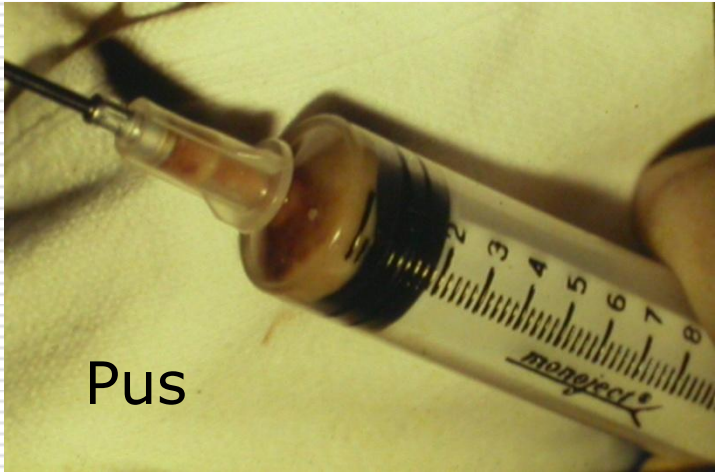
- ❑ Should not be used as a substitute for a conventional biopsy because of the false-negative results –
 - ❑ ***True Positive, False Negative***
 - ❑ The technique consists of scrapping the lesion with a tongue blade or spatula and spreading the scrapping over a glass slide, which is fixed immediately in 95% ethyl alcohol, then allow to dry in air and examined
-

Fine Needle Aspiration Biopsy

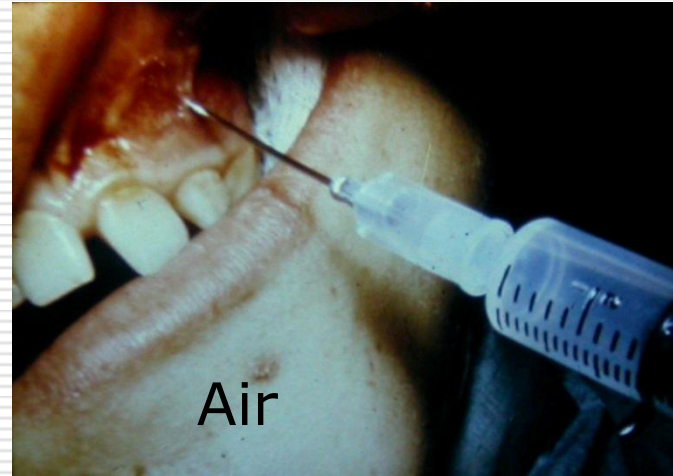
- ❑ Aspiration of cells or fluid for subsequent analysis
- ❑ Technique consists of repeatedly passing a needle, under negative pressure, through a lesion to collect cells
- ❑ Fluid aspirated from a lesion can also be sampled
- ❑ Generally requires analysis by a cytopathologist
- ❑ Indications:
 - Salivary gland masses
 - Neck masses
 - Aspiration of jaw cysts or other lesions



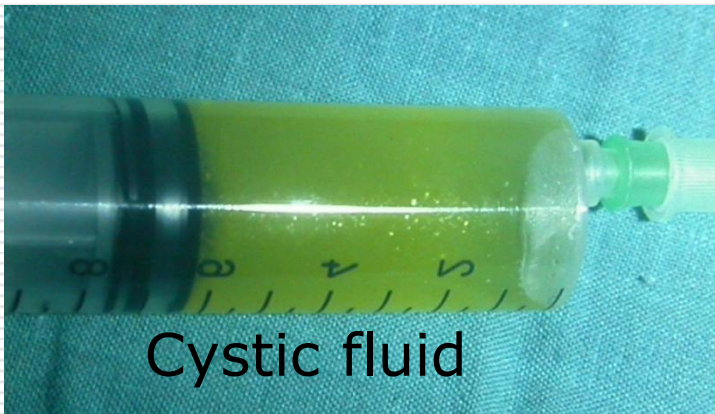
Aspiration Biopsy



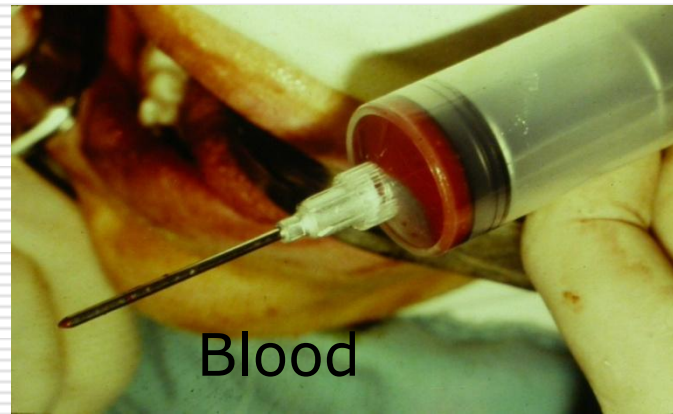
Pus



Air



Cystic fluid



Blood

Aspiration Biopsy

- When applied to jaw lesions:
 - **Air** suggestive of traumatic bone cyst
 - **Straw coloured fluid**: cyst
 - **Pus** : inflammatory or infectious process
 - **Blood, under high pressure**: suggestive of high flow vascular lesion.
 - **Blood, under low pressure**: aneurismal bone cysts, central giant cell granulomas
-

Types of Biopsy

□ ***Area of surgical removal:***

- ***Incisional biopsy:*** consists of the removal of a representative sample of the lesion and normal adjacent tissue in order to make a definitive diagnosis before treatment
 - ***Excisional biopsy:*** is aimed at the complete surgical removal of the lesion for diagnostic and therapeutic purposes
-

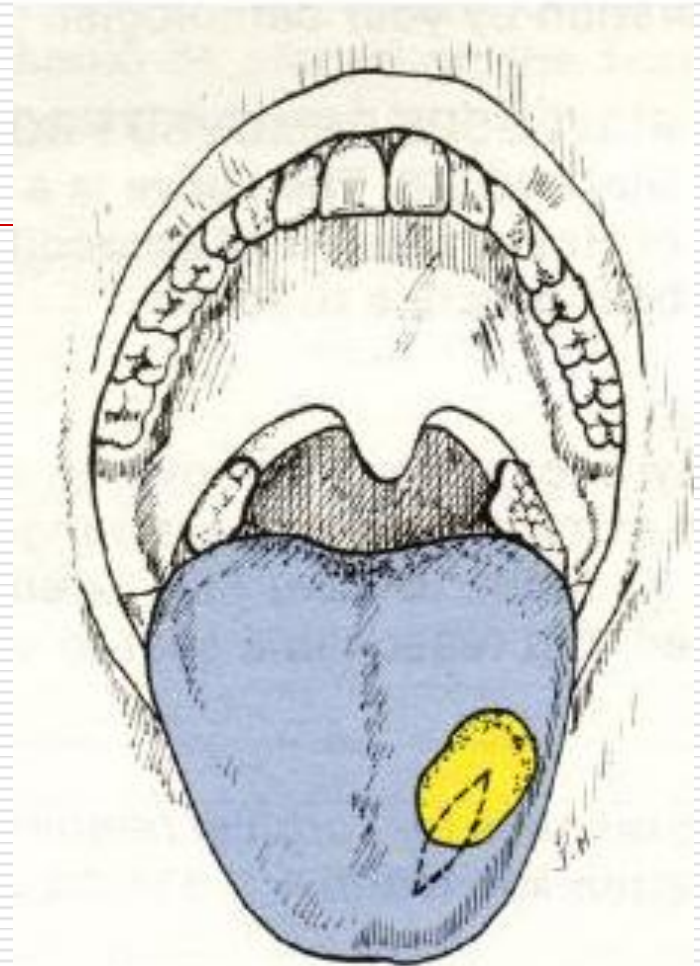
□ ***Timing of the biopsy:***

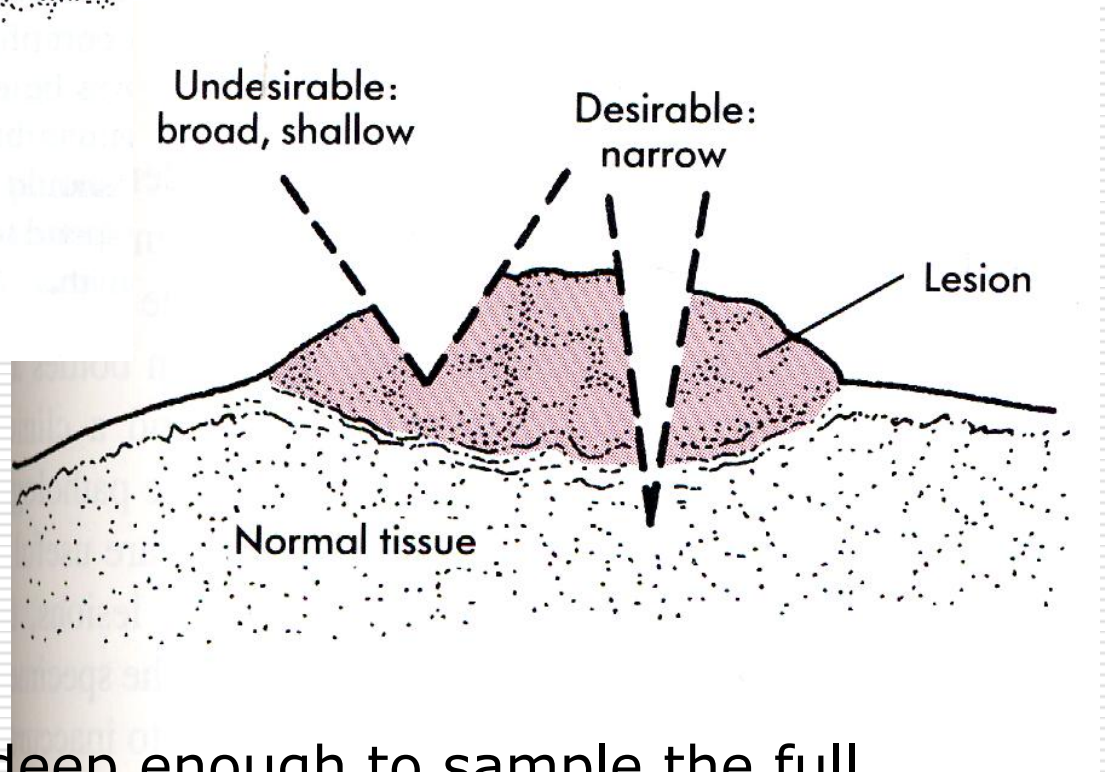
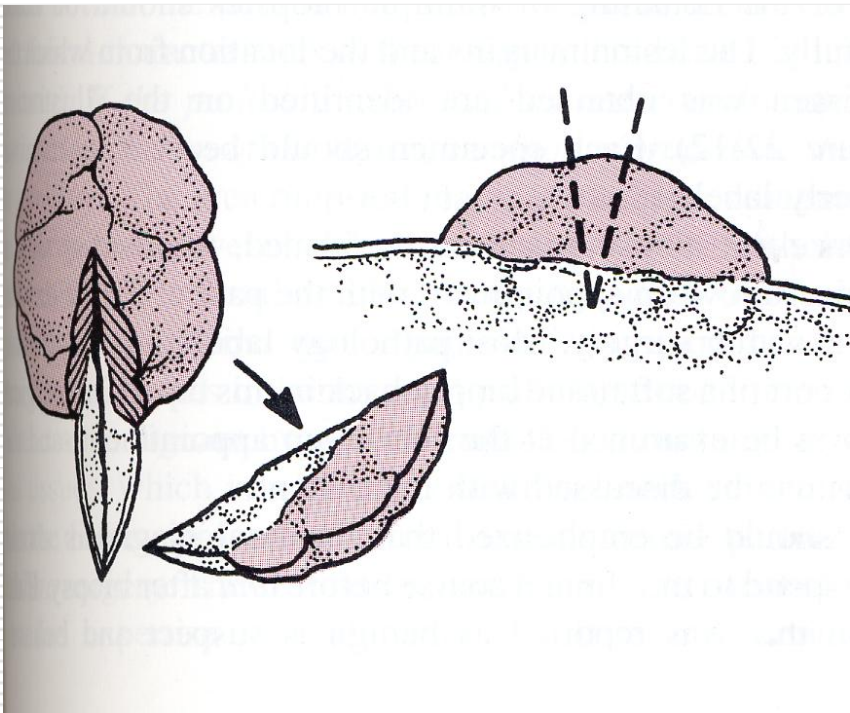
- Pre-operative
 - Intra-operative
 - Post-operative when aimed at checking the efficiency of a treatment
-

Incisional Biopsy

- Technique simple, only a portion of the lesion is removed
 - ***Indications:***
 - Large lesions with more than 1cm in diameter
 - Hazardous location
 - Malignancy suspected
-

-
- ❑ Biopsy of a wedge of representative tissue
 - ❑ Several regions may be sampled
 - ❑ Avoid necrotic tissue
 - ❑ Areas of tissue transition can be useful, such as the margin of the lesion
-



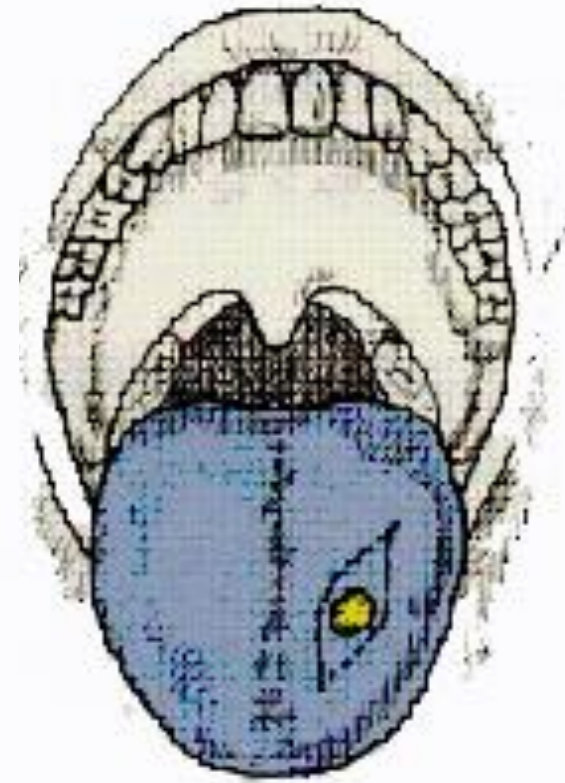
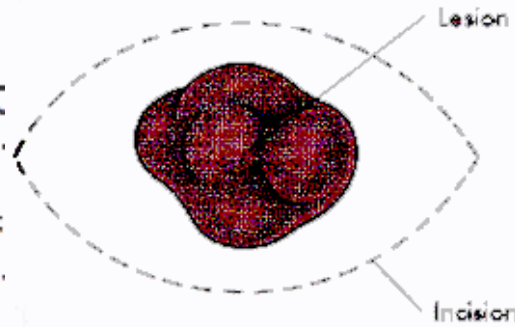
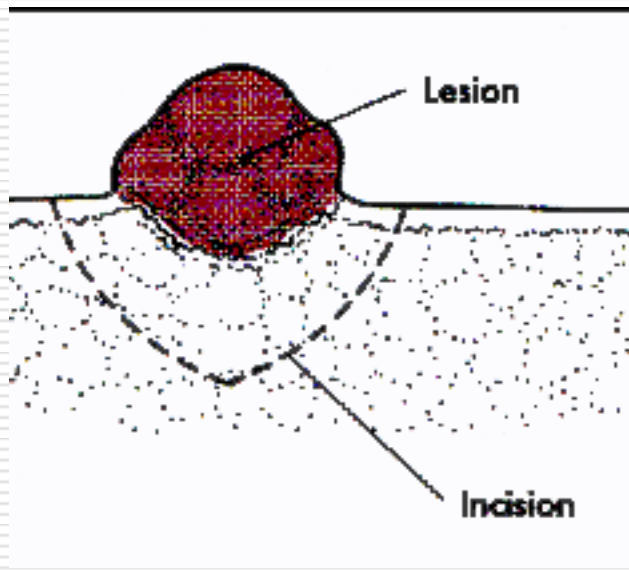


- Wedge should be deep enough to sample the full depth of the lesion and its transition to normal tissue

Excisional Biopsy

- ❑ Removes the entire lesion at the time of tissue sampling
- ❑ A margin of normal tissue is generally included
- ❑ Offers the advantage of definitive treatment at the time of diagnosis
- ❑ ***Indications:***
 - Smaller lesions, < 1cm
 - Pigmented and small vascular lesions
 - Benign lesions

Principle: lesion and 2-3mm margin of normal tissue is excised



- Elliptical incision is carried-out allowing for a narrow rim of normal peripheral tissue
- Beveling your incisions to a narrow "V" base facilitates wound closure

