ORAL HISTOLOGY & EMBRYOLOGY

PRACTICAL GUIDE

PROF. M. LOTFY

2012

ORAL HISTOLOGY & EMBRIOLOGY

PRACTICAL GUIDE

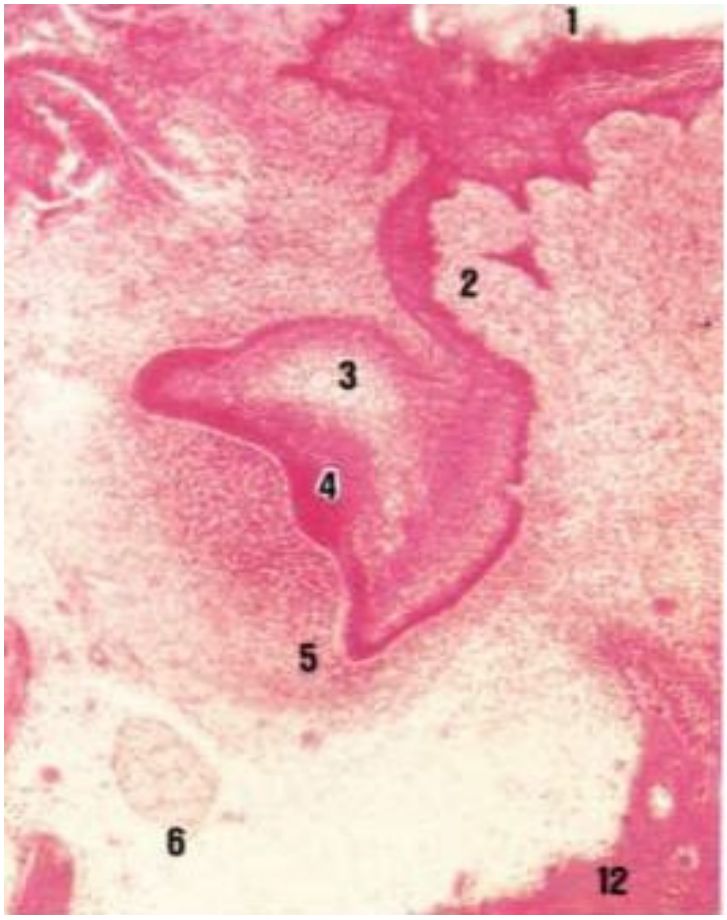

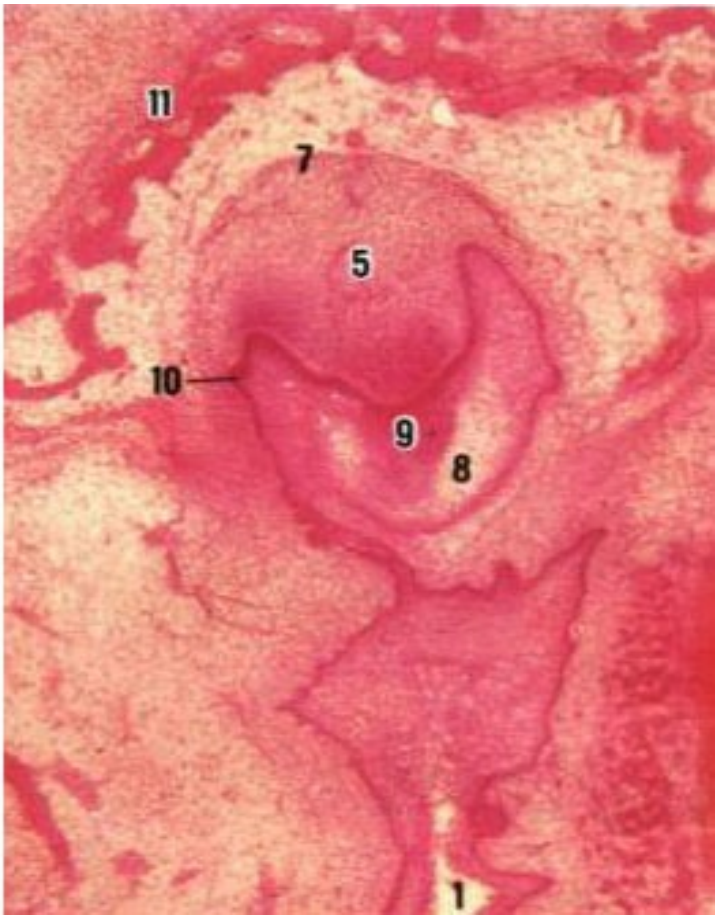

Tooth Development

Slide 1

The cells of the stellate reticulum near the inner enamel epithelium proliferate to form a transient structure called the enamel knot (4) (left)

The cells of the enamel knot continue to proliferate to form the transient enamel cord which extends to the enamel navel. They form at the site of the future cusp tip

1. Oral mucosa
2. Dental lamina
3. Enamel organ
4. Enamel knot
5. Dental papillae
6. Inferior alveolar nerve
7. Dental sac of dental follicle
8. Enamel organ
9. Enamel cord
10. Successional dental lamina
11. Maxillary bone
12. Mandibular bone

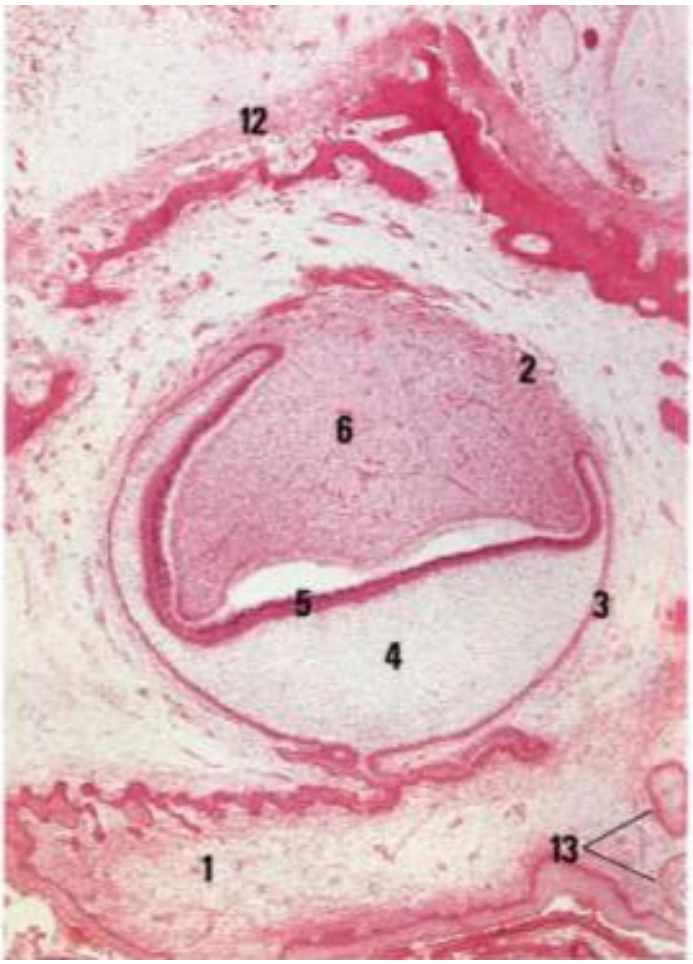

Slide 2

Frontal section of primary canine tooth germ of 13-week fetus (left) and primary lateral incisor (right). H&E stain

Infolding of outer enamel epithelium at the enamel navel brings blood vessels in the mesenchyme closer to the cells of the enamel cord.

The cells in the center of the enamel organ produce hydrophilic proteoglycans which, with the influx of water, separates them from each other. The cells become stellate-shaped. This region is called the stellate reticulum.

1. Dental lamina
2. Dental sac or follicle
3. Outer enamel epithelium
4. Stellate reticulum
5. inner enamel epithelium
6. Dental papillae
7. Enamel cord
8. Enamel navel
9. Blood vessel
10. Enamel niche
11. Successional dental lamina
12. Incisive bone
13. Nasopalatine duct

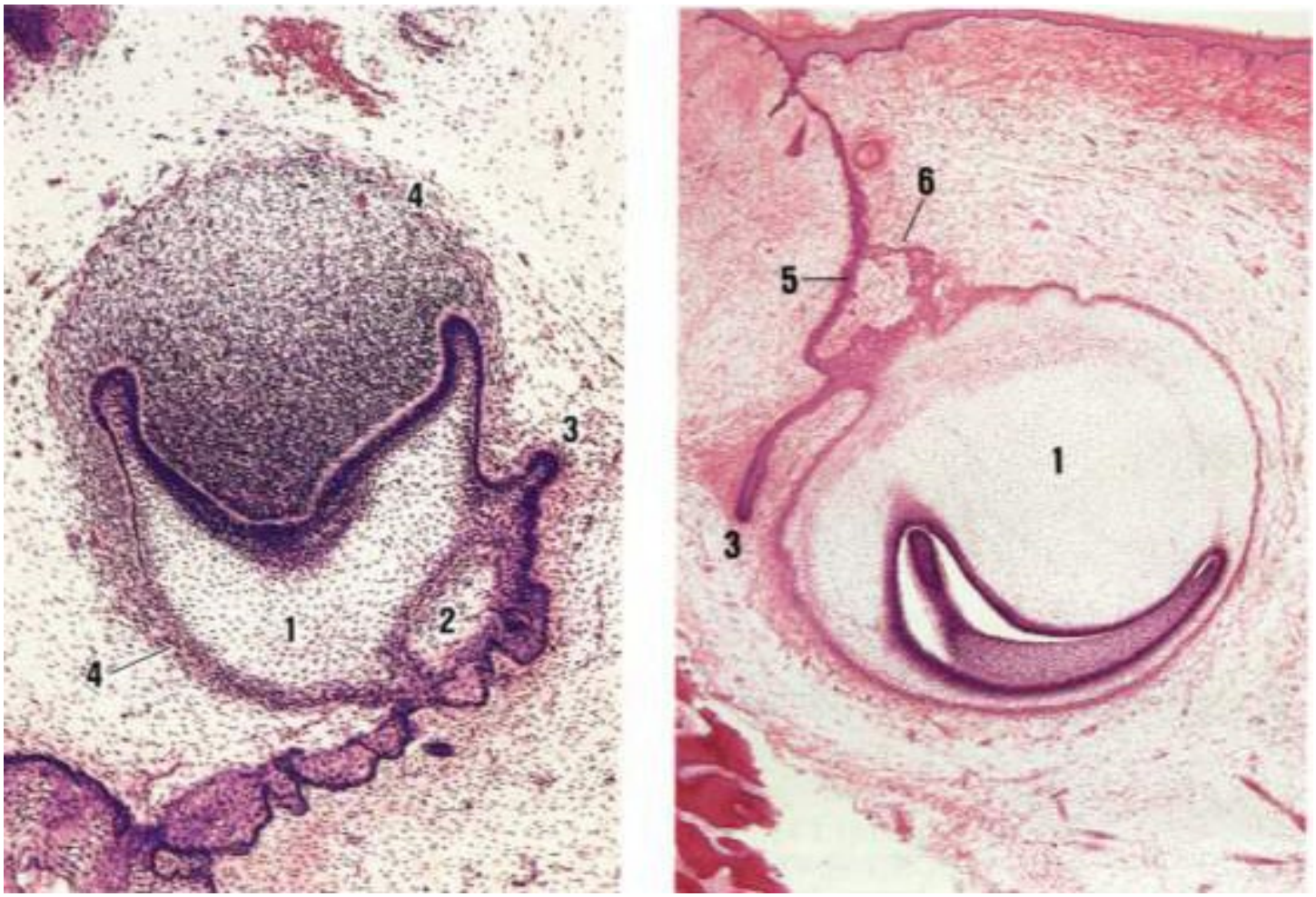

Slide 3

Frontal section of the tooth germ of aq primary lateral incisor of an 11-week human embryo (left) and of a primary first molar of an 18-week human embryo (H&E –X200 – X140)

A fibrovascular membranous structure, the dental follicle (4), surrounds the enamel organ and the dental papilla. Cells of the follicle will produce cementum and the periodontal ligament. Mesenchymal proliferation produces depression on the mesial and distal sides of the dental lamina known as enamel niche (2). The successional dental lamina also appears at this time. The continued expansion of the enamel niche divides the dental lamina into a medial and lateral lamina.

1. Stellate reticulum (enamel pulp)
2. Enamel niche
3. Successional dental lamina
4. Dental follicle
5. Medial dental lamina
6. Lateral dental lamina

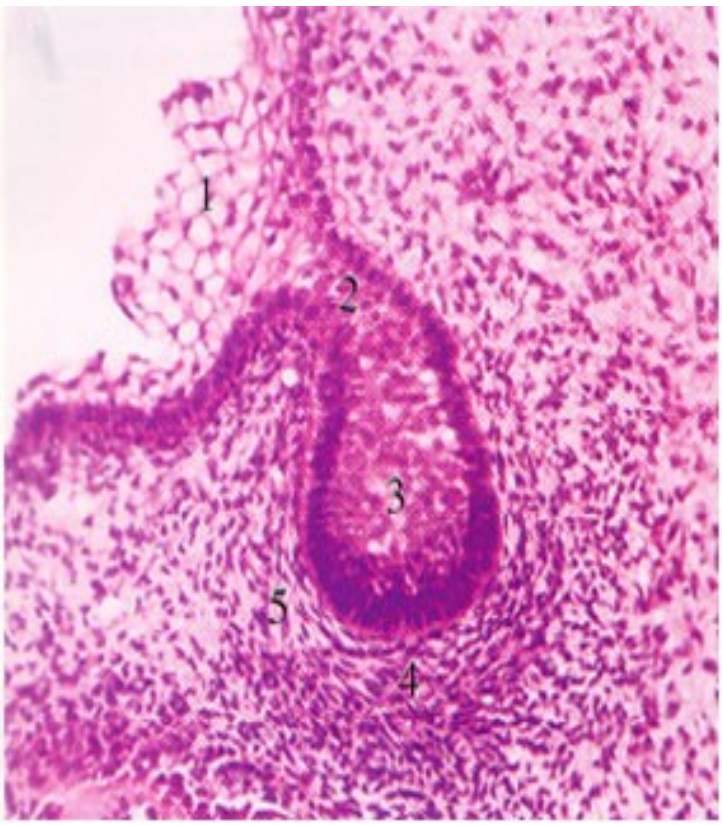

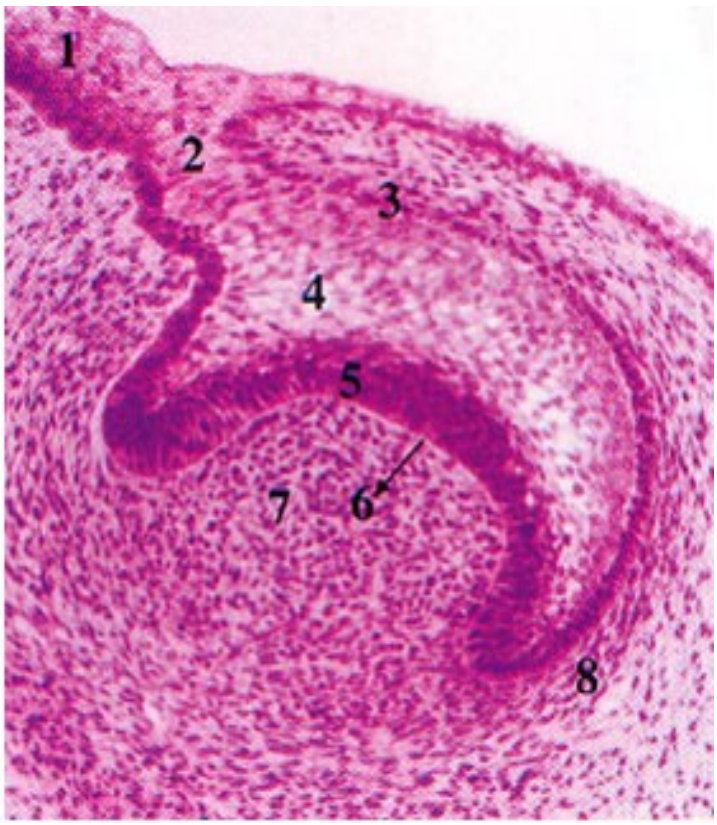

Slide 4

A. Bud Stage

1. Oral epithelium
2. Dental lamina
3. Tooth bud (dental organ)
4. Dental papilla
5. Dental sac

B. Cap Stage

1. Oral epithelium
2. Dental lamina
3. Outer dental epithelium
4. Stellate reticulum
5. Inner dental epithelium
6. Cell free zone
7. Dental papilla
8. Dental sac

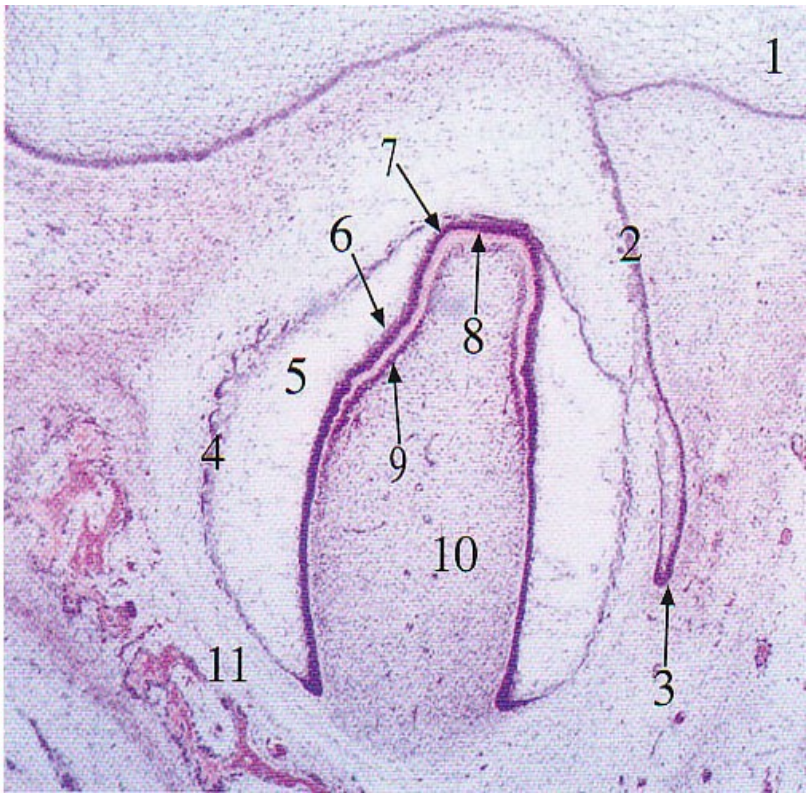

Slide 5

A. Early Bell Stage (Left)

1. Oral epithelium
2. Lateral dental lamina
3. Primordium of permanent tooth
4. Outer dental epith.
5. Stellate reticulum
6. Inner dental epith.
7. Dental papilla
8. Dental sac

B. Late Bell Stage (Right)

1. Oral epithelium
2. Lat. dental lamina
3. Primordium of permanent tooth
4. Outer dental epith.
5. Stellate reticulum
6. Stratum intermedium
7. Inner dental epith.
8. Predintin
9. Odontoblast
10. 11. dental papilla & sac

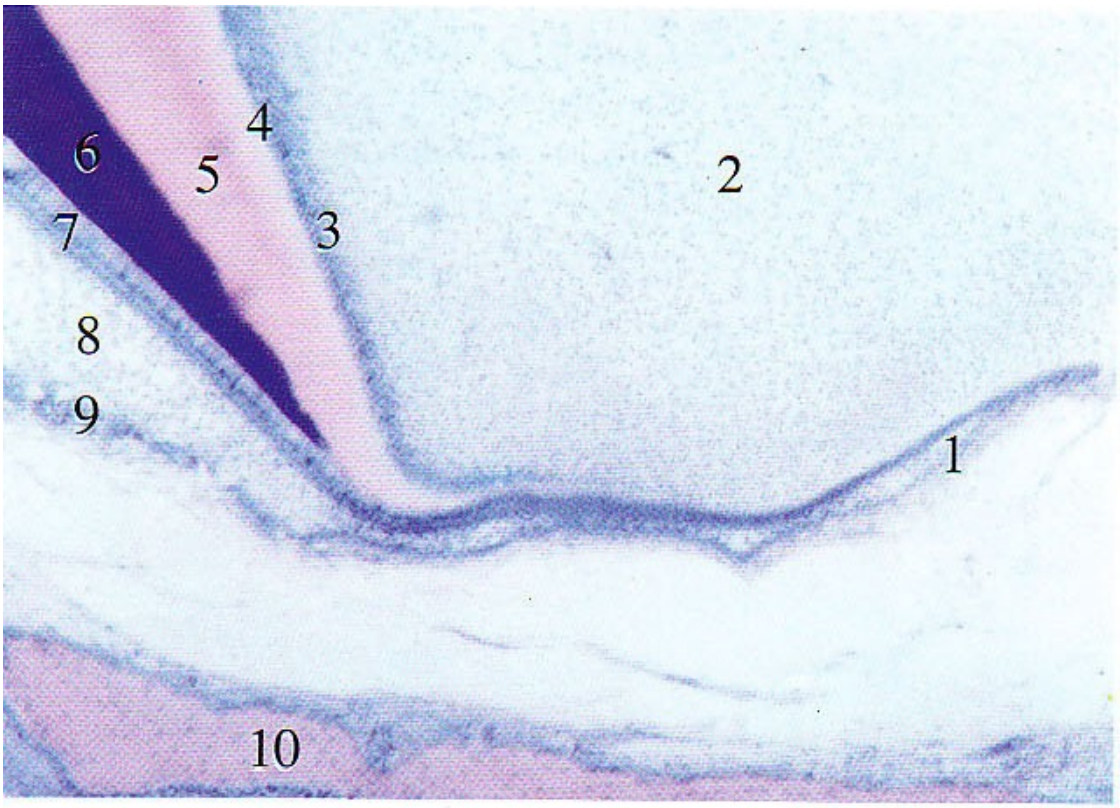

Slide 6.
Root Formation

1. Epithelium diaphragm
2. Dental papilla
3. Odontoblasts
4. Predentin
5. Dentin
6. Enamel matrix
7. Ameloblasts
8. Stellate reticulum
9. Outer dental epith.
10. Bony crypt

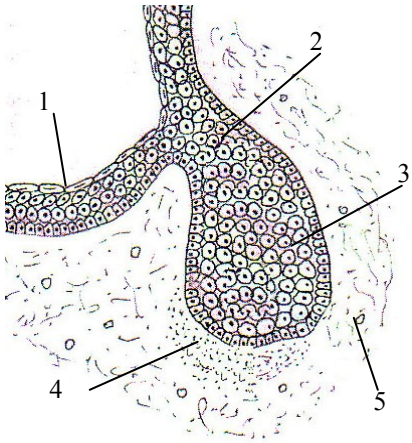

Diagram I.
Bud Stage

1. Oral epithelium
2. Dental lamina
3. Dental organ
4. Dental papilla
5. Dental sac

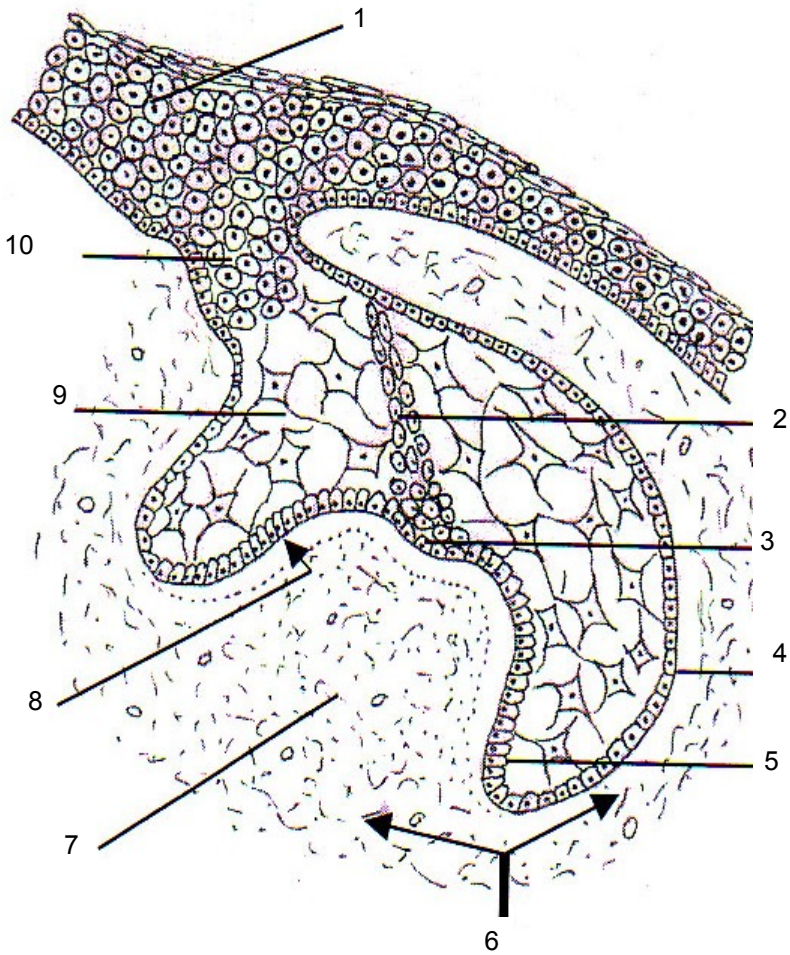

Diagram II.
Cap Stage

1. Oral epithelium
2. Enamel cord
3. Enamel knot
4. Outer inner epithelium
5. Inner enamel epithelium
6. Dental sac
7. Dental papilla
8. Cell free zone
9. Stellate reticulum
10. Dental lamina

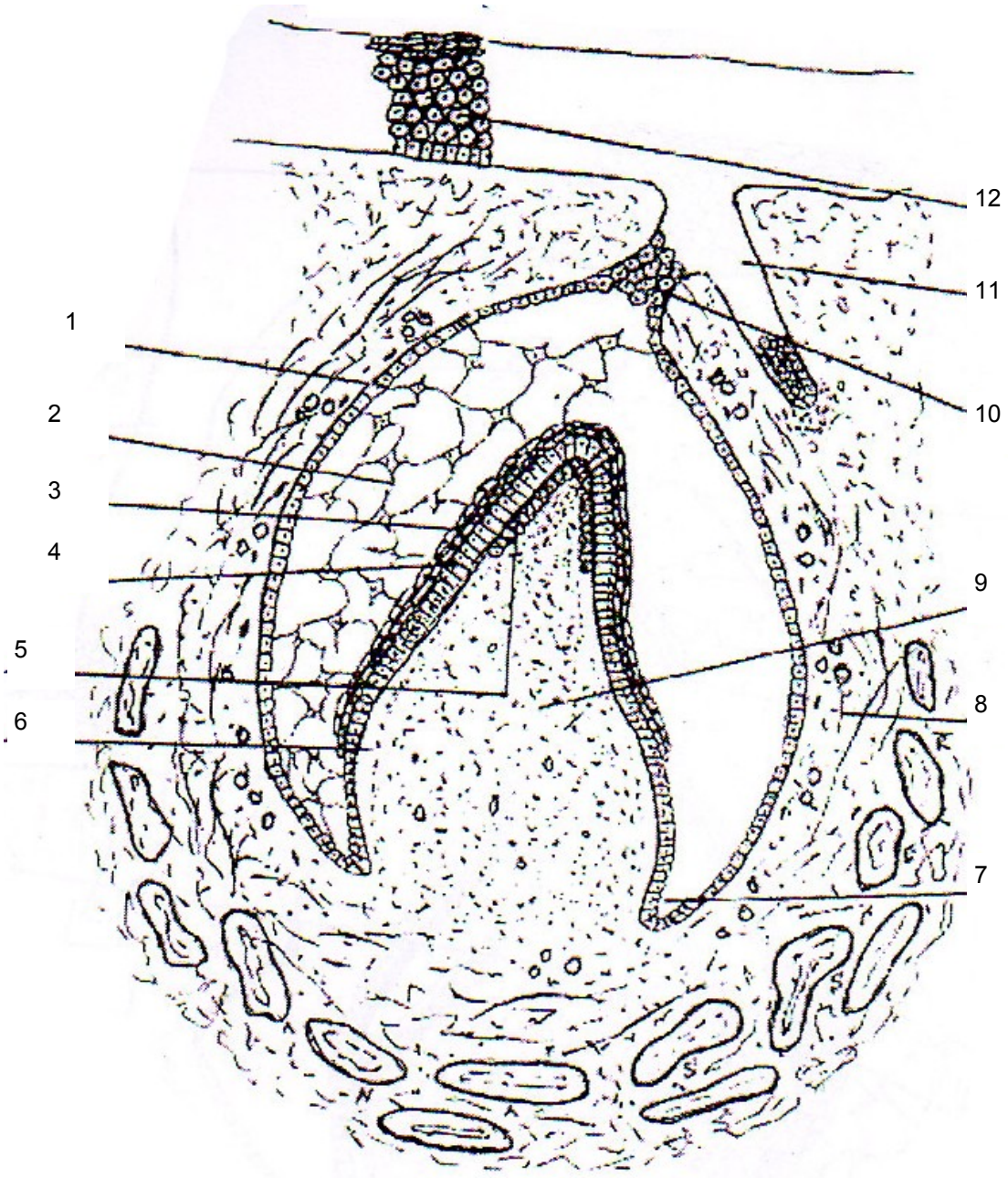

Diagram III
Early Bell Stage

1. Outer dental epithelium
2. Stellate reticulum
3. Stratum intermedium
4. Inner dental epithelium
5. Odontoblasts
6. Cell free zone
7. Cervical loop
8. Dental sac
9. Dental papillae
10. Lateral dental lamina
11. Main dental lamina
12. Oral epithelium

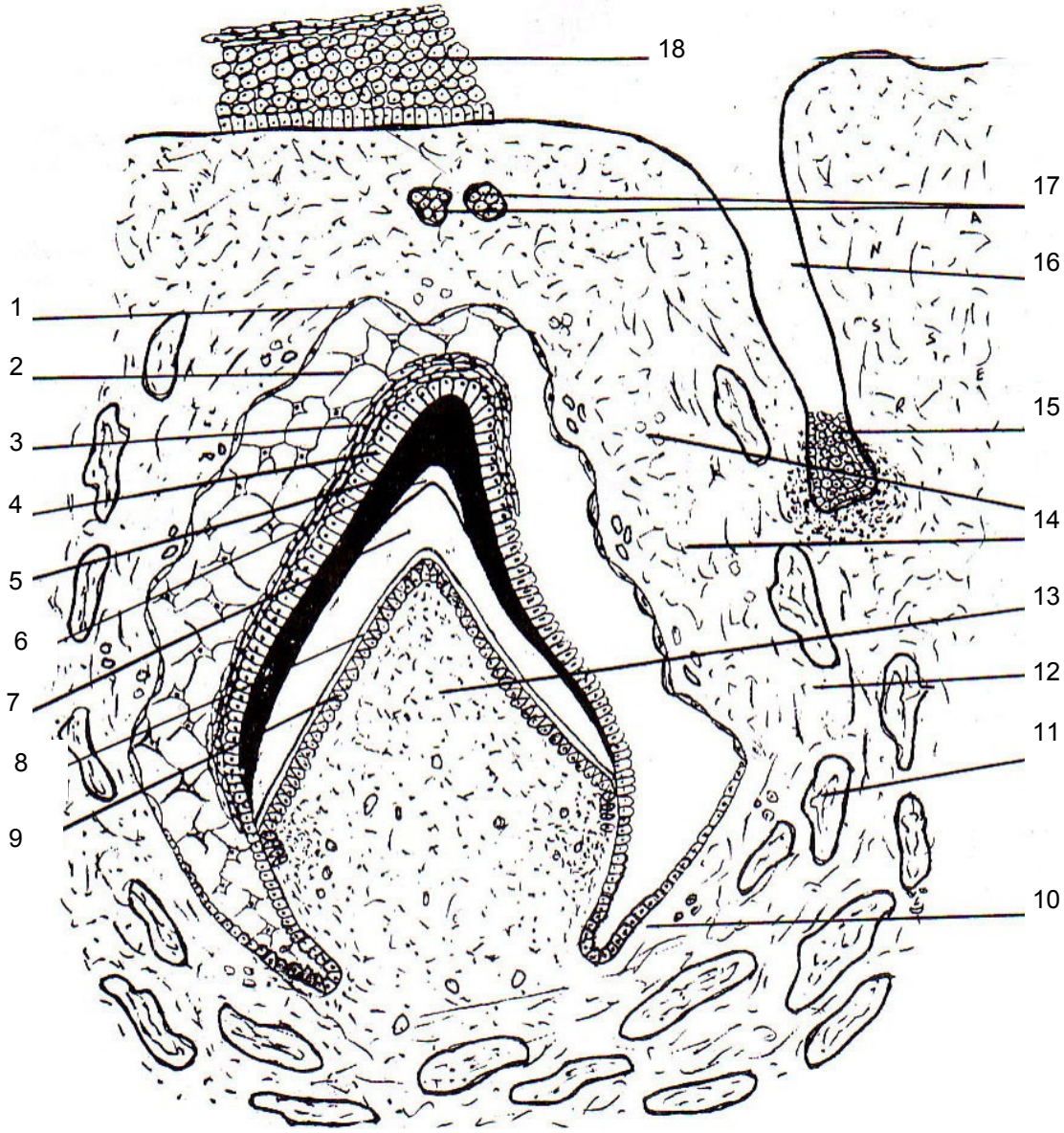

Diagram IV
Late Bell Stage

1. Outer dental epithelium
2. Stellate reticulum
3. Stratum intermedium
4. Ameloblasts
5. Enamel matrix
6. Enamel space
7. Dentin
8. Predentin
9. Odontoblasts
10. Cervical loop
11. Bone spicules
12. Dental sac
13. Dental papilla
14. Capillary loops
15. Successional dental lamina
16. Main dental lamina
17. Epithelial rests of Serres'
18. Oral epithelium

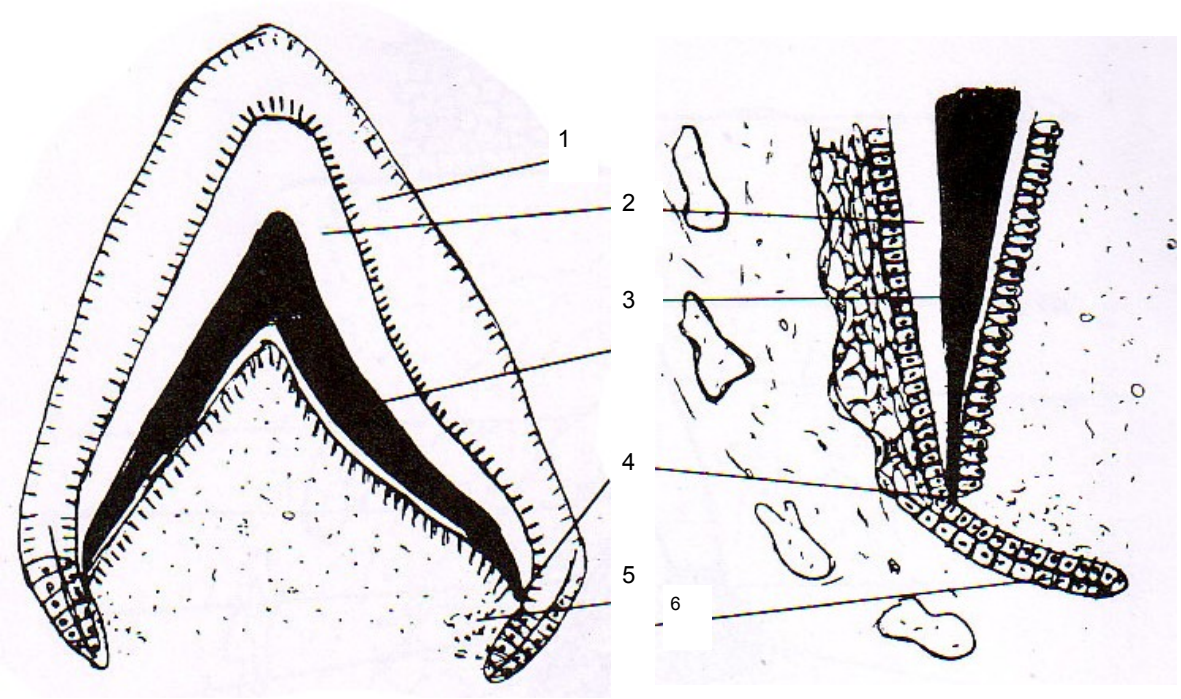

Diagram V
Root Formation

1. Dental organ
2. Enamel matrix
3. Dentin
4. Future cement enamel junction
5. Proliferating zone
6. Epithelial diaphragm

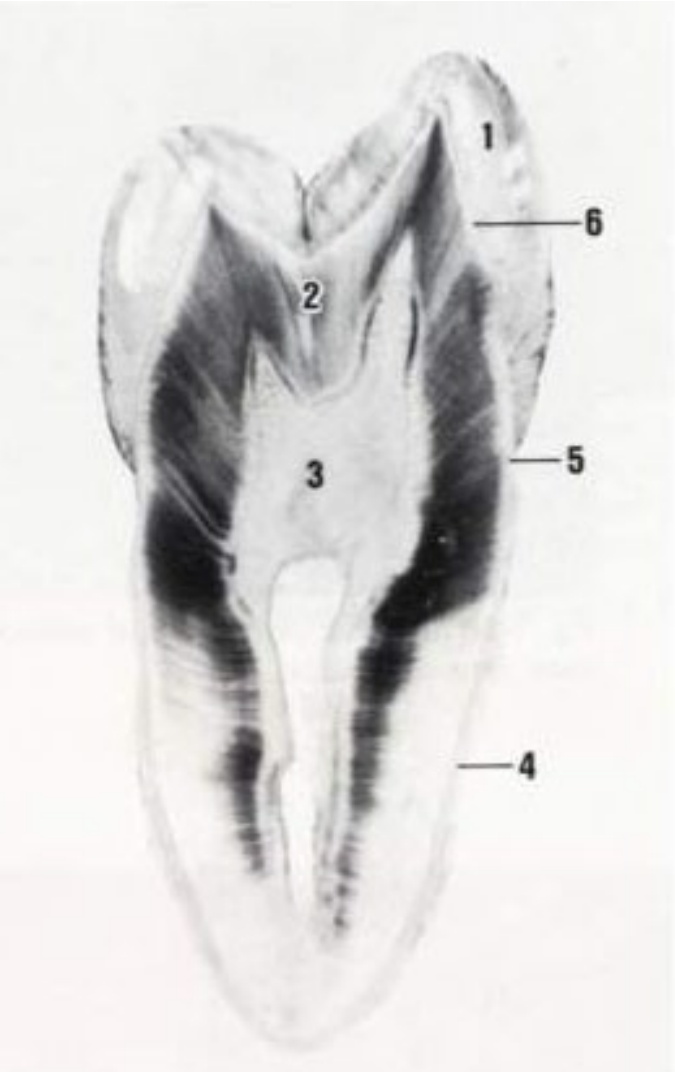

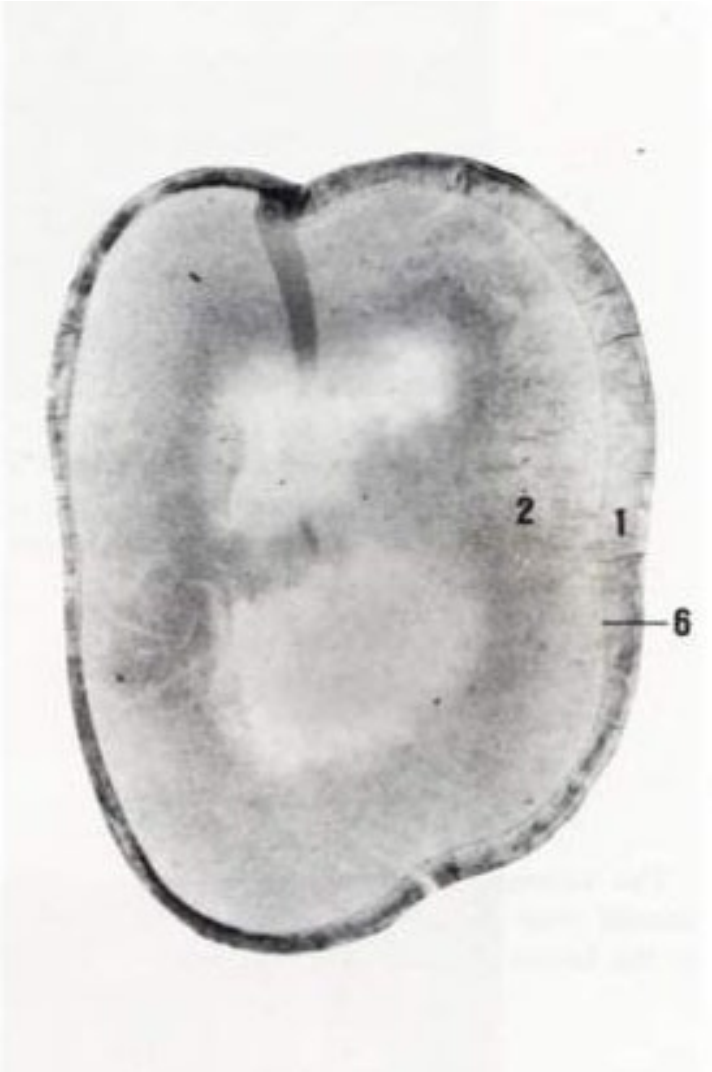

ENAMEL

Slide 7

Longitudinal mesio-distal ground section of maxillary second premolar X6 (left) and transverse section of the crown of the first maxillary molar (right)

1. Enamel
2. Dentin
3. Pulp cavity
4. Cementum
5. Cement-enamel junction
6. Dentino-enamel junction



Slide 8

Longitudinal ground section of enamel rods. Cross striation and striae of Retzius are shown in this ground section X800. (left)

Cross striations are perpendicular to the long axis of the enamel rods. Several lines or striae of Retzius course obliquely across the enamel rods.

Micrograph of an incisal edge of a longitudinal ground section, the lines or striae of Retzius at the incisal edge do not reach the surface but arch over the tip of the dentinoenamel junction.

1. Cross striation
2. Striae of Retzius



Slide 9

Longitudinal ground section of enamel rods. The enamel rod is 4-6 micron in width X1500

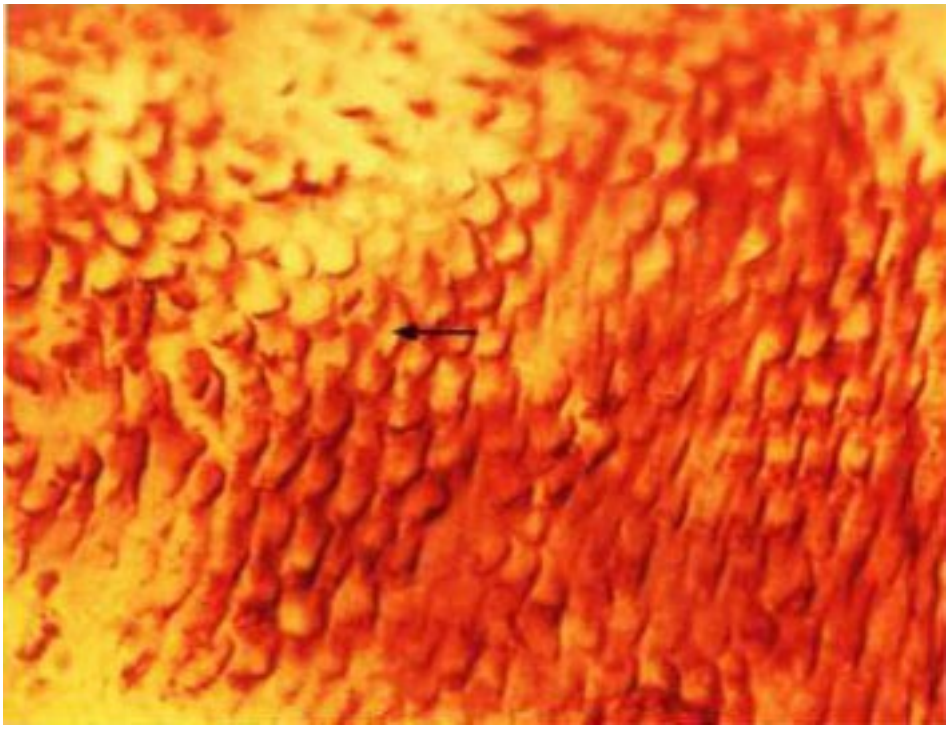

Slide 10

Cross and oblique section of enamel rods. Ground section X1200. Enamel rods cut perpendicular to their long axis appear as arcades or keyholes.

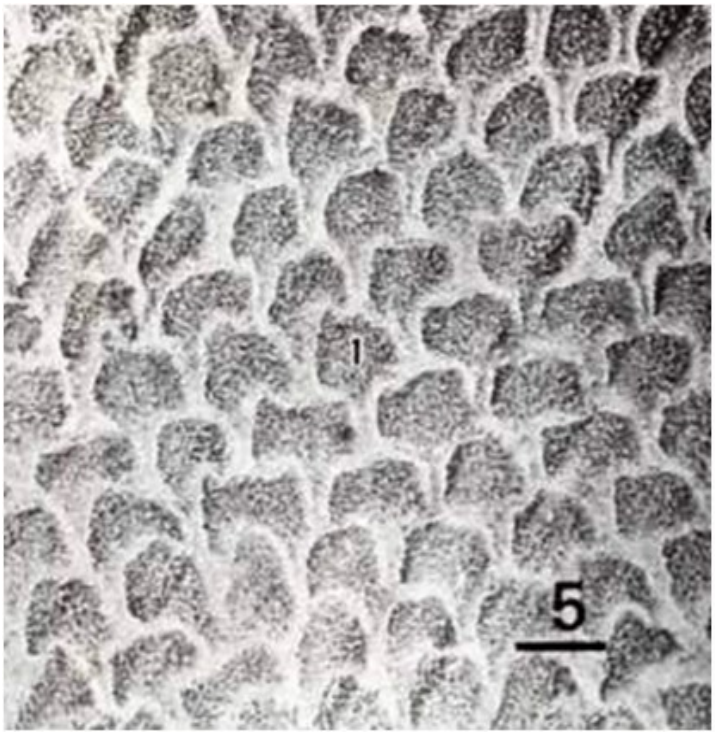

Slide 11

Scanning electron micrograph of itched transverse sectioned enamel rods. X3500. (left). In the mid coronal region of the crown, the enamel rods appear as keyhole shaped structures. Higher magnification X10000. (right)

Transverse section enamel rods are divided into two parts head and tail. The tail is located between adjacent heads and corresponds to interrod enamel. The enamel rod seath encloses the head and contains organic matrix and recrystalized hydroxyapatite crystals which are more aci-resistant. The rod sheath appears as a ridge.

1. Enamel rod
2. Enamel rod head,
3. Enamel rod tail,
4. Enamel hydroxyapatite crystal
5. Enamel rod sheath

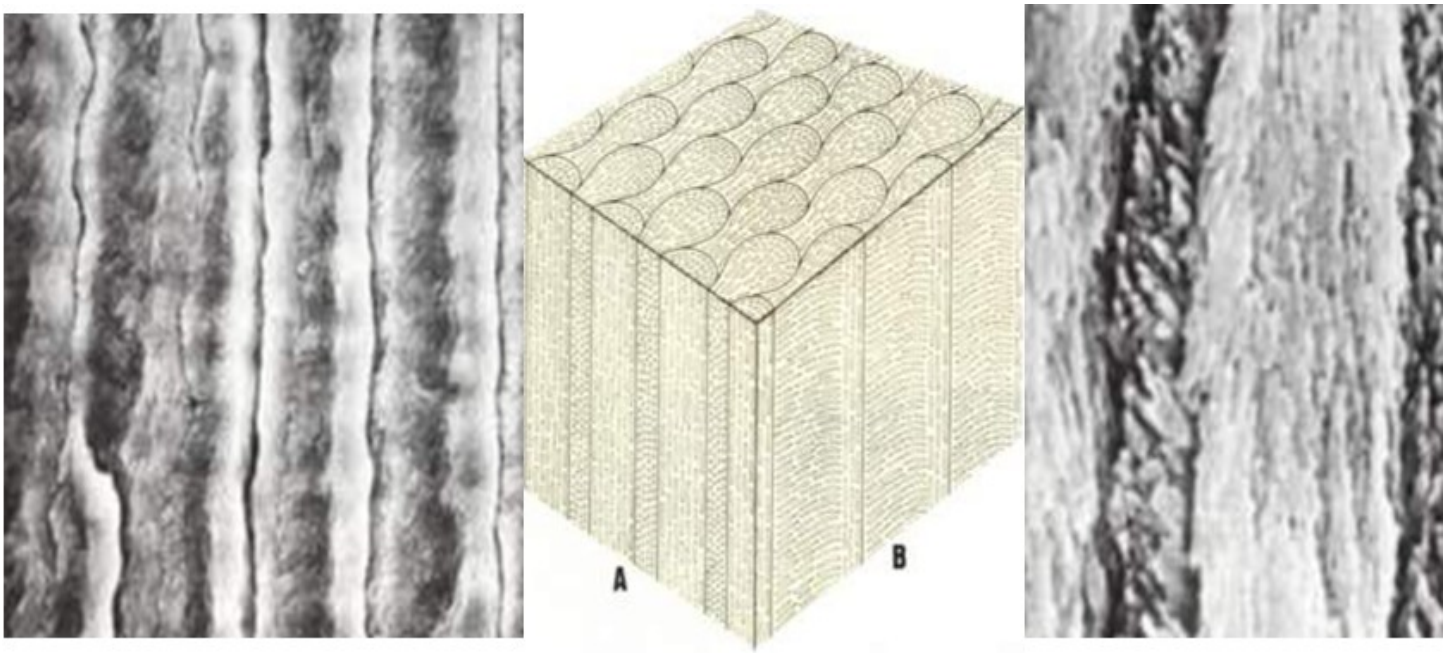

Slide 12

The orientation of the hydroxyapatite crystals varies according to the plane of section and the location within the enamel rod.

This diagram shows the crustal orientation within a block of enamel cut in three plans perpendicular to each other (middle)

On face A enamel rods are cut parallel to their long axis. The crystals in the heads are cut lengthwise while those in the tails are cut obliquely (left) X2000.

On face B enamel rods are cut perpendicular to their long axis. Crystals in the head are cut lengthwise while those in the heads are cut transversely. (right) X4000)

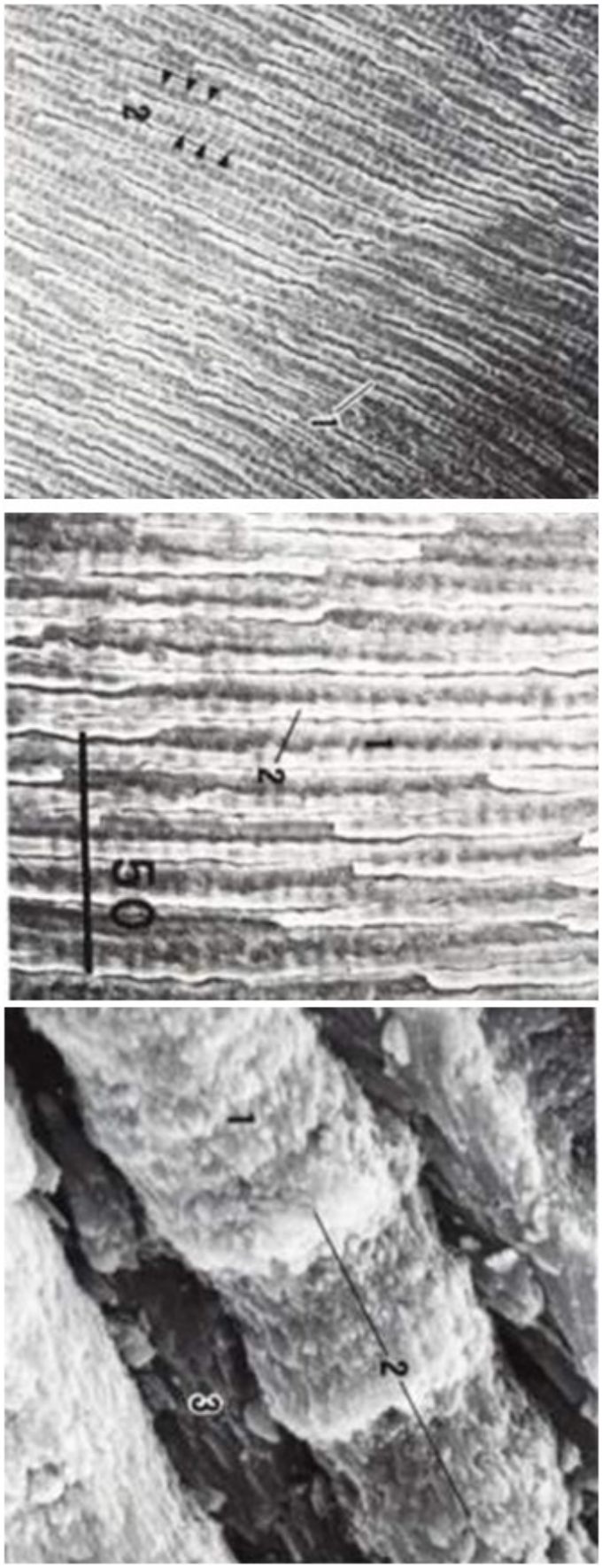

Slide 13

Scanning electron micrograph of an itched longitudinal ground section of enamel rods, cross striation are indicated by arrow heads (left) X800

Higher magnification are shown in the middle micrograph X1500. the enamel rod is divided into 4-6 micron blocks or segments by the cross striation (dark bands) (middle)

More higher magnification x7000 (right) shows cross striations as varicosities.

The pattern of cross striation denotes the daily deposition of enamel matrix. The expansion seen along the enamel rod may be produced by a slowing of the backward movement of the ameloblasts.

1. Enamel rod
2. Cross striation
3. Interred substance

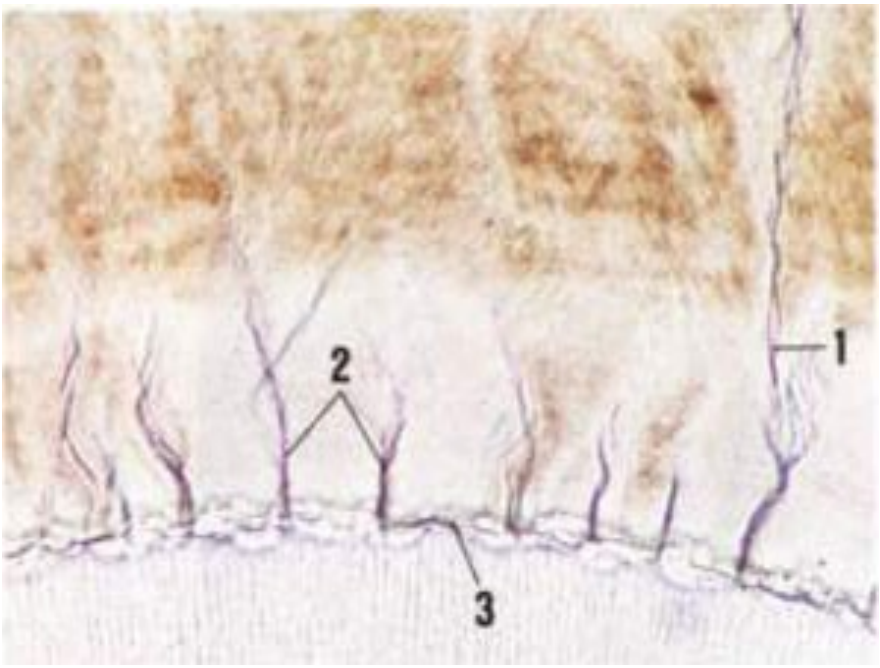

Slide 15
Enamel Tufts

Enamel tufts originate at the dintinoenamel junction and extend into the enamel for about one third of its thickness. Their distribution is semi-regular around the junction. Enamel lamellae extend from the surface of the tooth and may reach into the dentine. They are randomly distributed and usually filled with organic material from the saliva.

To the right is a micrograph of transverse ground section along the dentinoenamel junction demonstrating enamel tuffs and enamel lamellae (X100)

1. Enamel lamella
2. Enamel tuft
3. Dentinoenamel junction

Slide 14
Enamel Spindles

Some of the dentinal tubules extend for a short distance into the enamel and appear as dilated twisted structures called the enamel spindles. They are usually filled with air during the tissue preparation and appear dark.

To the left is a micrograph of a transverse ground section along the dentinoenamel junction. The enamel spindles are oriented obliquely to the dentinal tubules. (X100)

1. Enamel spindle
2. Dintinoenamel junction

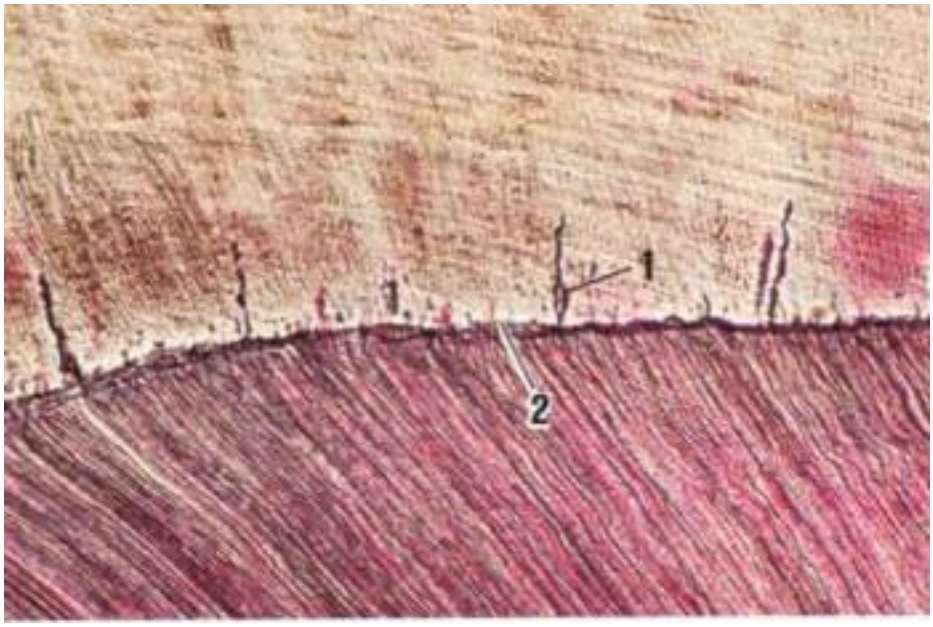

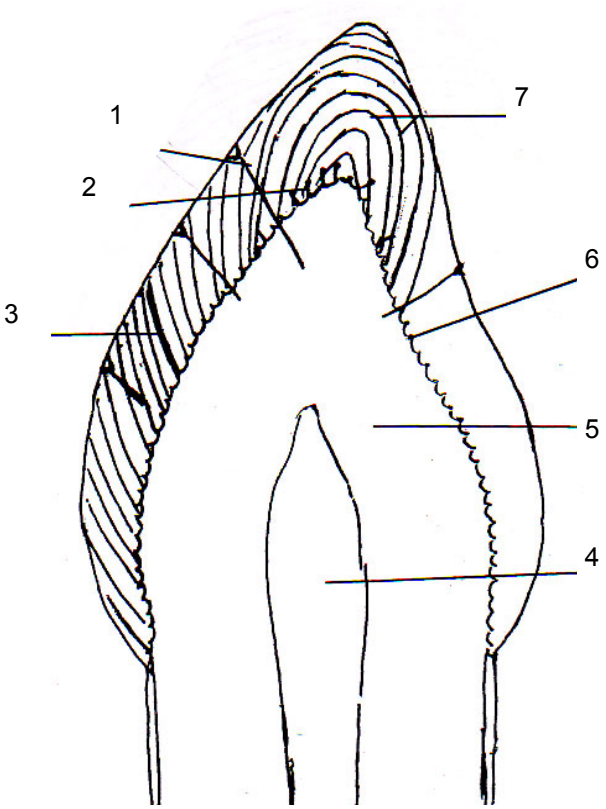

Diagram VI
Longitudinal Ground Section in Enamel

1. Enamel lamella
2. Enamel spindle
3. Neonatal line
4. Pulp space
5. Dentine
6. Dentinoenamel junction (DEJ)
7. Incremental line of Retzius (Brown stria of Retzius)

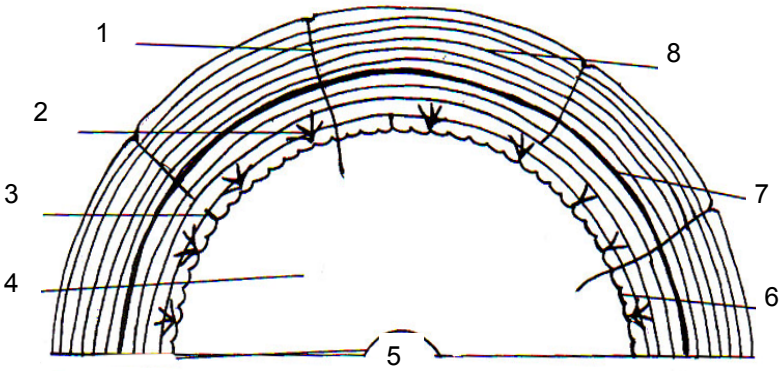

Diagram VII
Transverse Ground Section in Enamel

1. Enamel lamellae
2. Enamel tuft
3. Enamel spindle
4. Dentin
5. Pulp space
6. Dentinoenamel junction
7. Neonatal line
8. Incremental line of Retzius

Slide 16
Dentin-pulp Complex

1. Dentinal tubules
2. Incremental lines if von Ebner
3. Predentin
4. Odontoblasts
5. Pulp

Slide 17

1. Interglobular dentin
2. Dentinal tubules
3. Predentin
4. Odontoblasts
5. Pulp

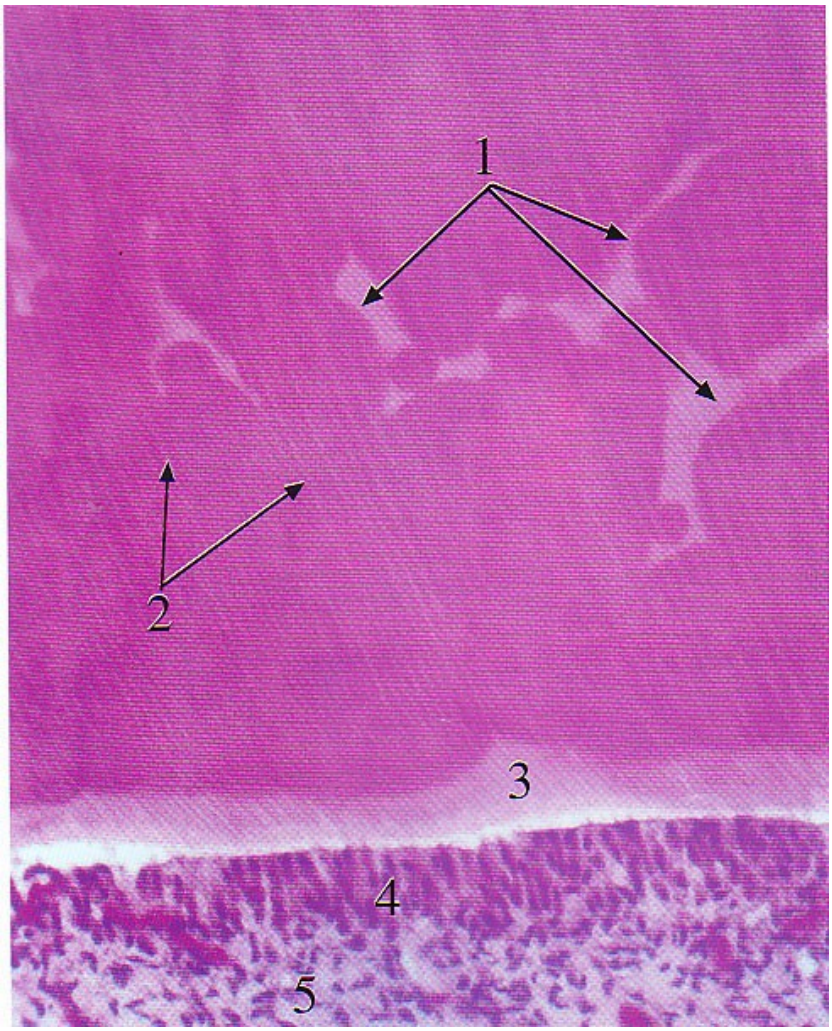

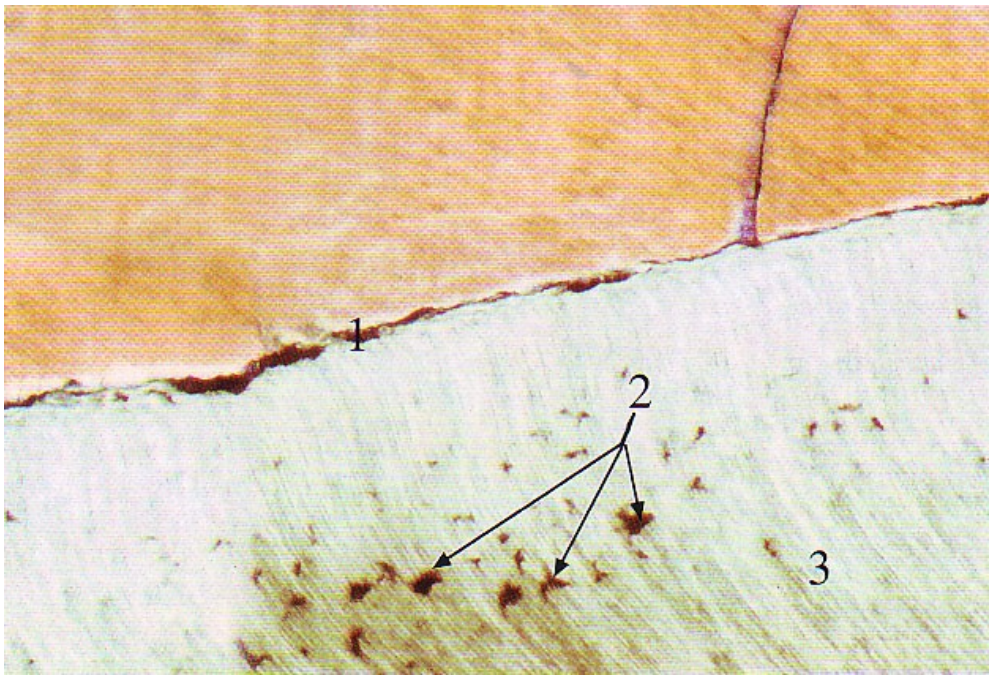

Slide 18
Longitudinal Ground Section in Dentin

1. Dentino-enamel junction
2. Interglobular dentin spaces
3. Dentinal tubules

Slide 19
Dentinal Tubules

The S-shaped course of the dentinal tubules.

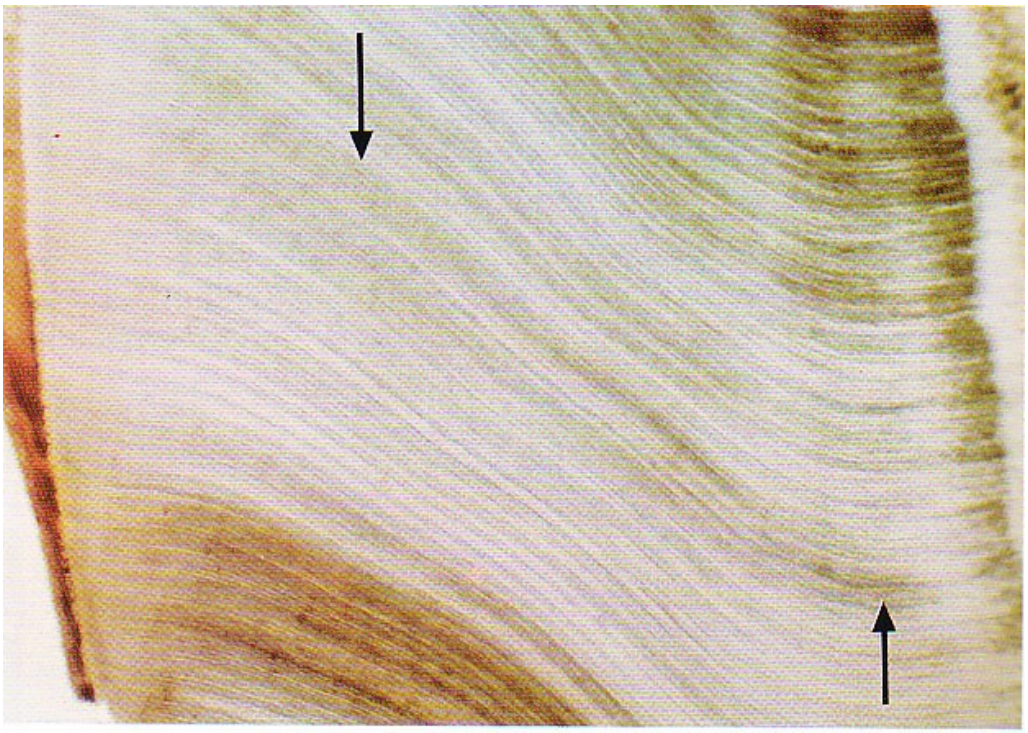

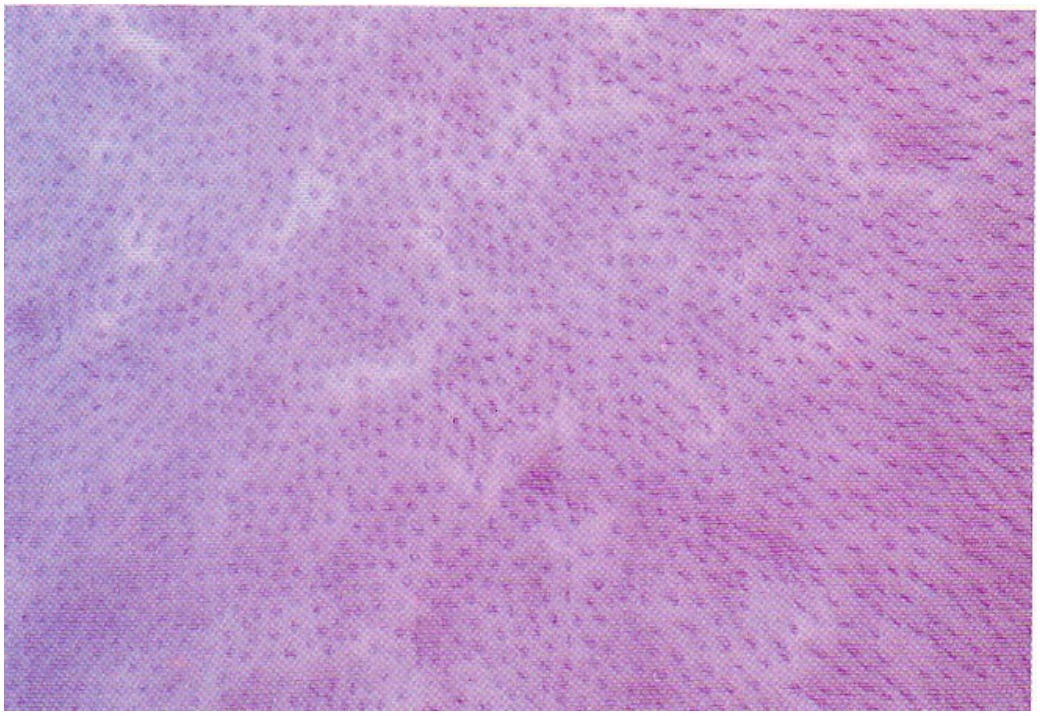

Slide 21
Interglobular Dentin

Demineralized section shoeing ehe network pattern of interglobular dentin. (H&R stain X 40)

1. Interglobular dentin network
2. Epithelial rests of Malassez
3. Alveolar bone

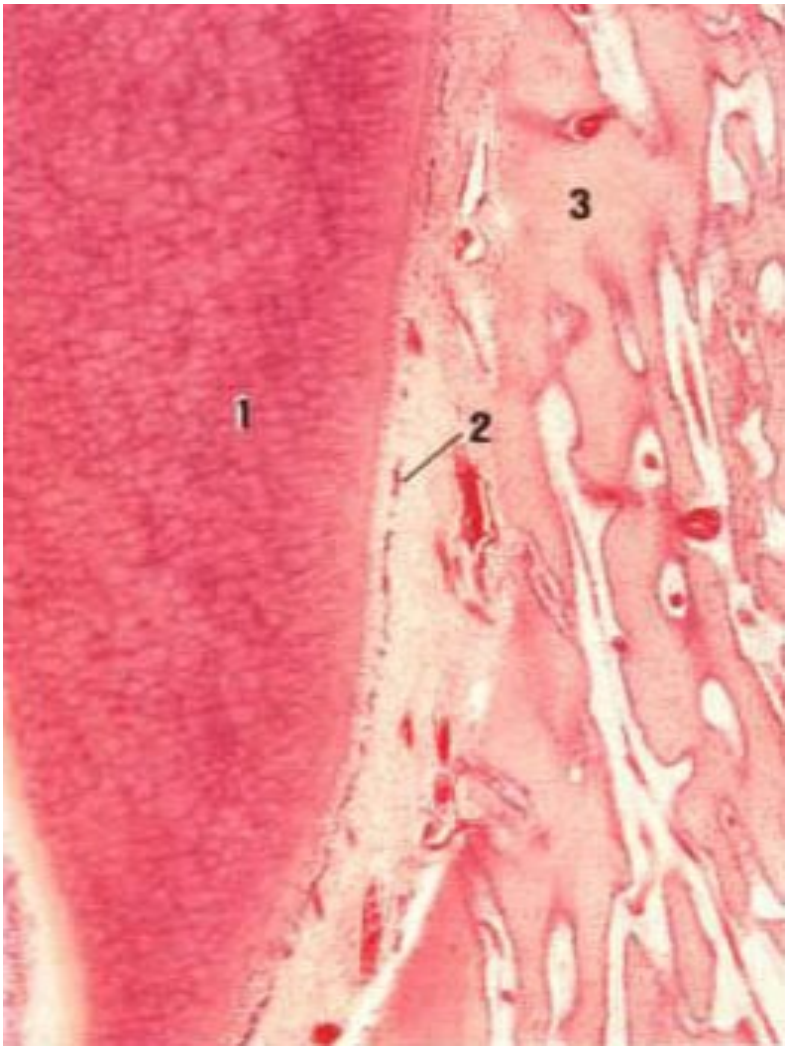

Slide 20
Dentinal Tubules

Transverse ground section in the dentinal tubules

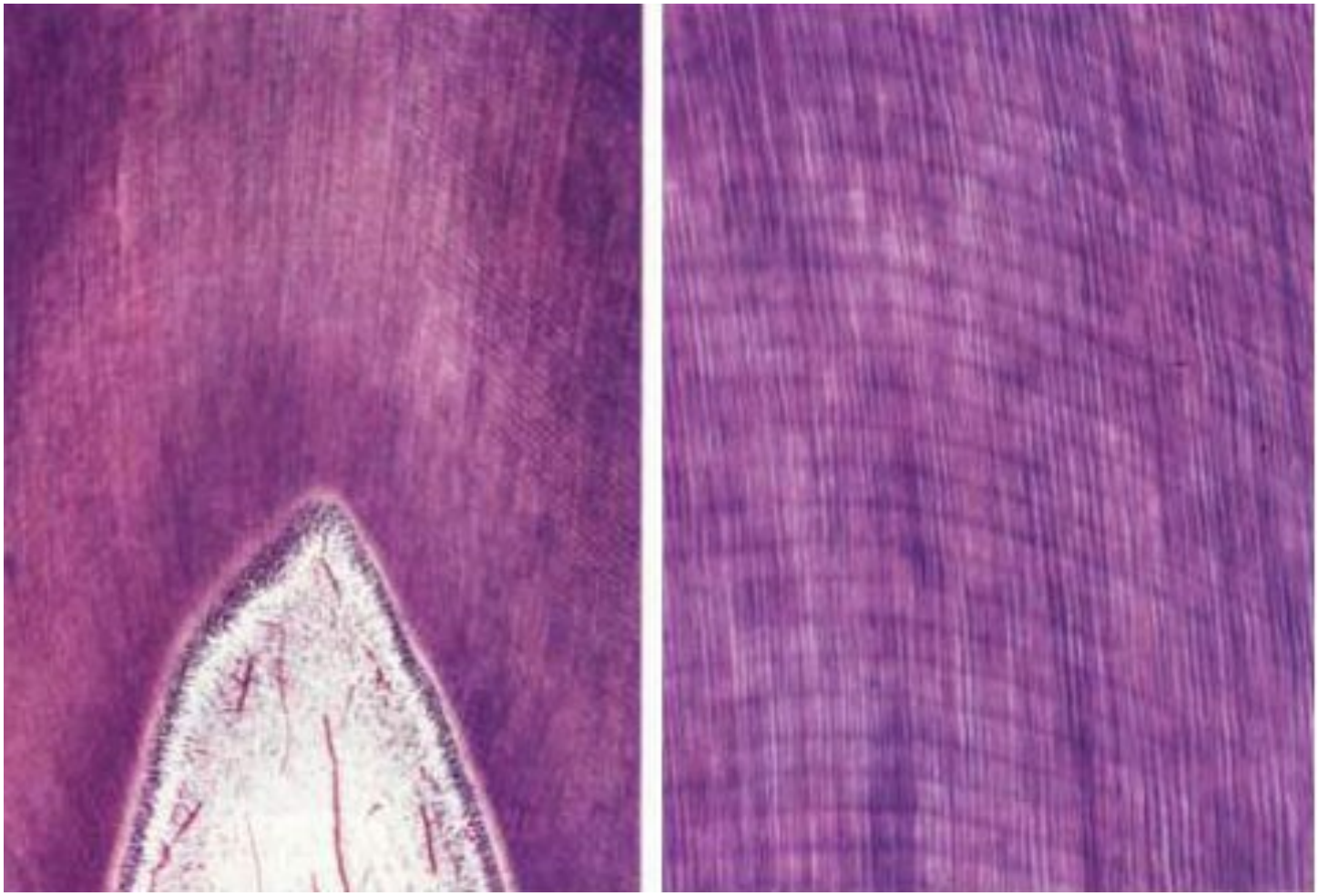

Slide 22
Lines of von Ebner

Demineralized section of dentin showing lines of von Ebner demonstrating the increment of dentin formation (H&E stain) X80 (left) and X300 (right)

Diagram VIII
Longitudinal Ground Section in Dentin

1. Enamel spindles
2. Dentino-enamel junction
3. Neonatal line
4. Intergloblar dentin space
5. Contour lines of Owen
6. Incremental line of con Ebner
7. Tome;s granular layer
8. Dentinal tubules\
9. Pulp space
10. cementum

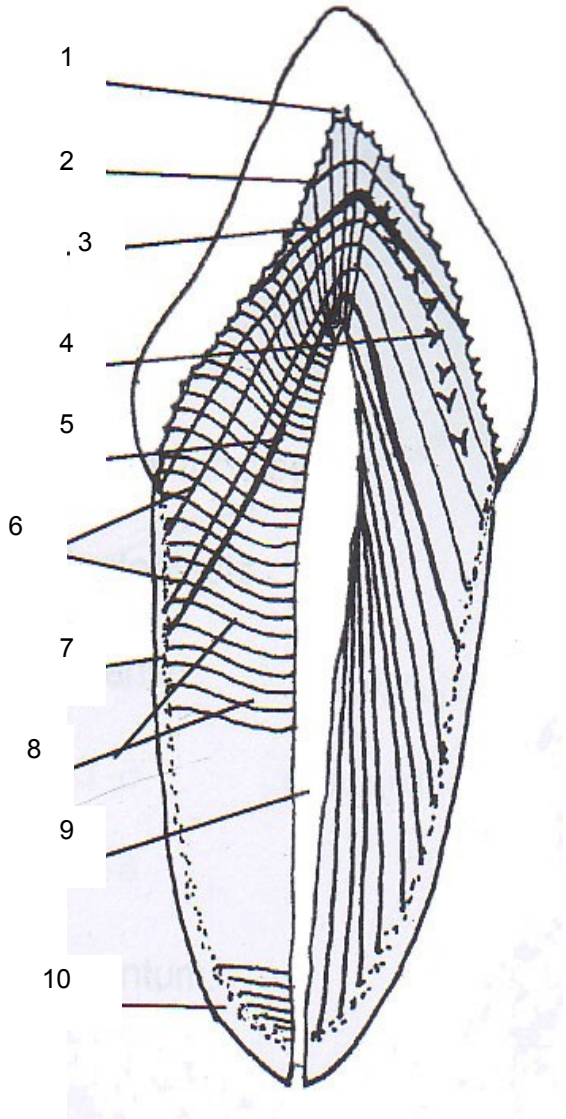

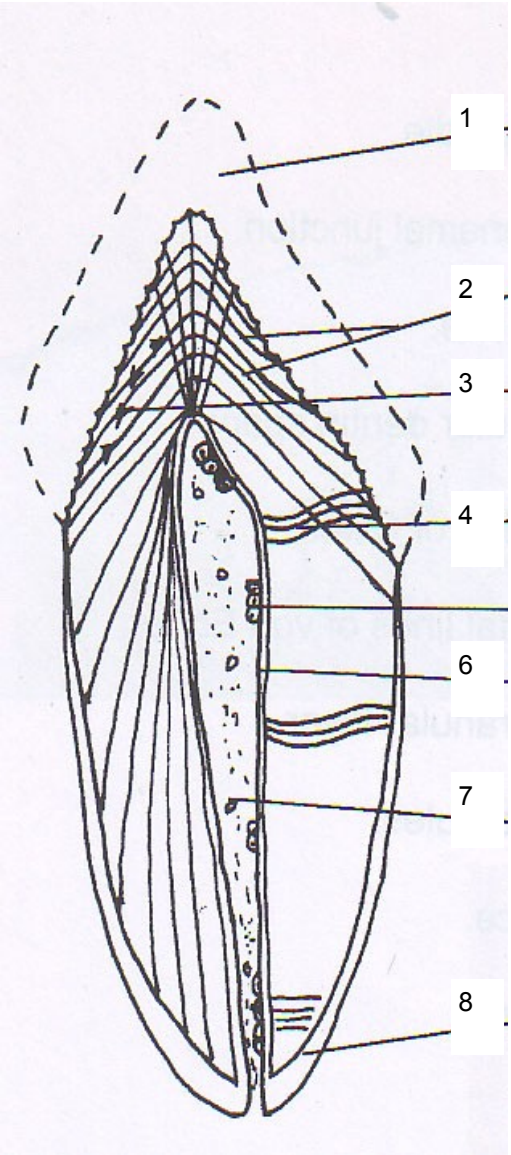

Diagram IX
Longitudinal Decalcified Section in Dentin

1. Enamel s[ace
2. Incremental line of con Ebner
3. Intergloblar dentin
4. Fintinal tubules
5. odontoblasts
6. Ptrdontin
7. Pulp
8. cementum

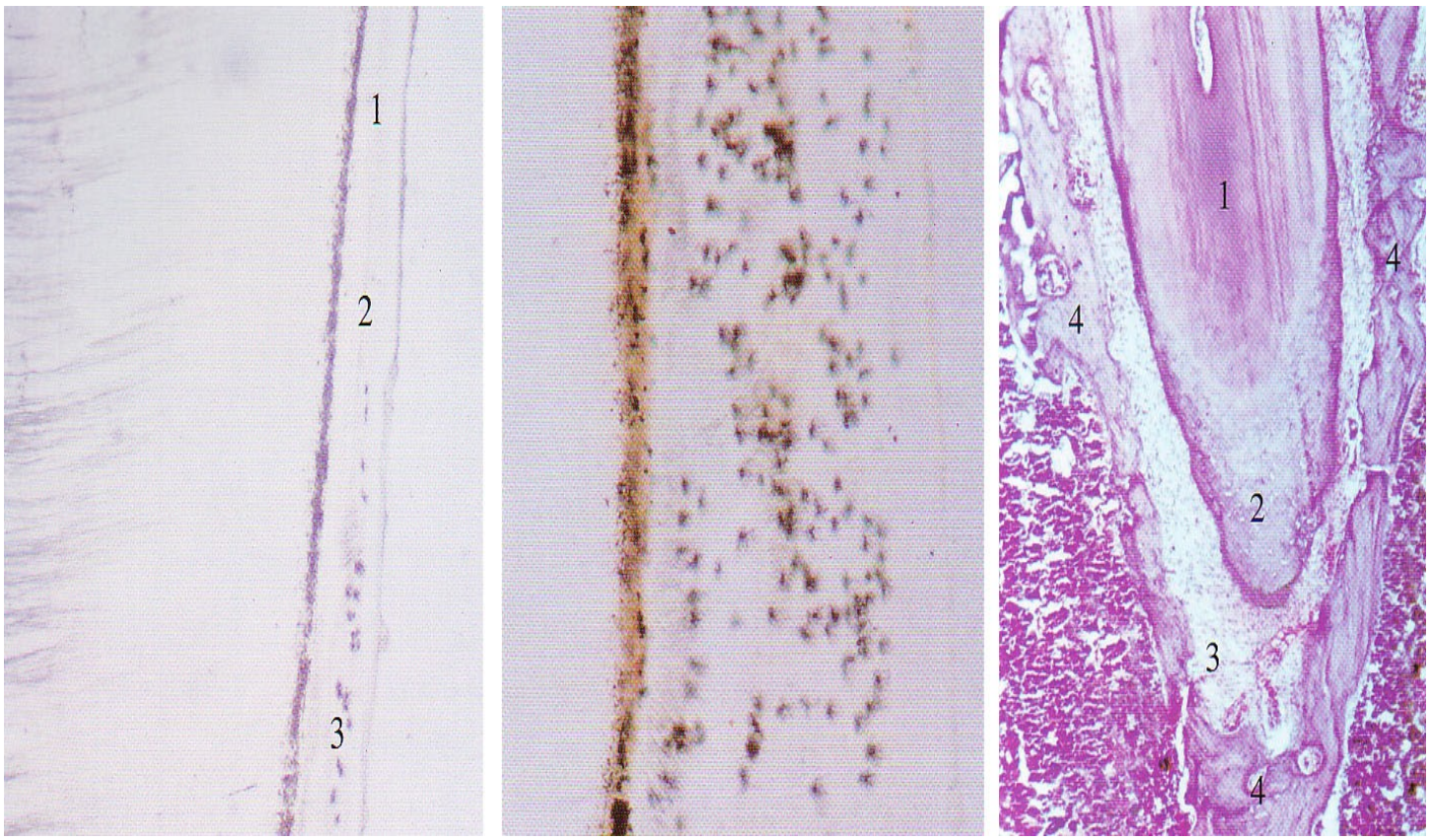

CEMENTUM

Slide 23

Cementum (left) 1. Acellular cementum, 2. Incremental lines of Salter, 3. Cellular cementum

Cemntocyte Lacunae (middle). Lacunae of cementocyte in cellular cementum (arrow)

Cellular cementum at the apex of the root

1. Dentin
2. Cellular cementum
3. Apical fibers of periodontal ligament
4. Alveolar bone

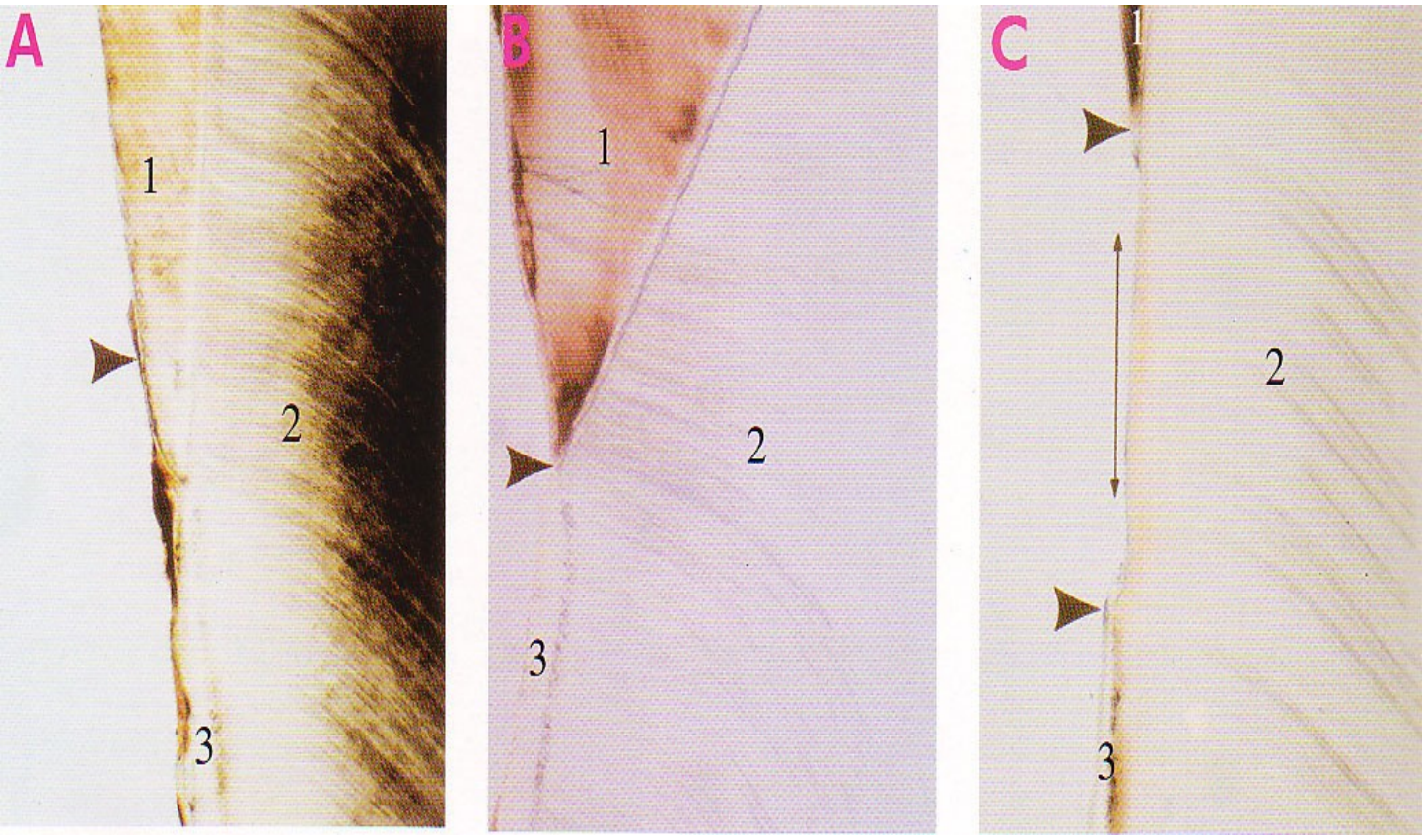

Slide 24
Cemento-Enamel Junction

A. cementum overlaps enamel

B. Cementum meets enamel

C. No junction

1. Enamel
2. Dentin
3. Cementum

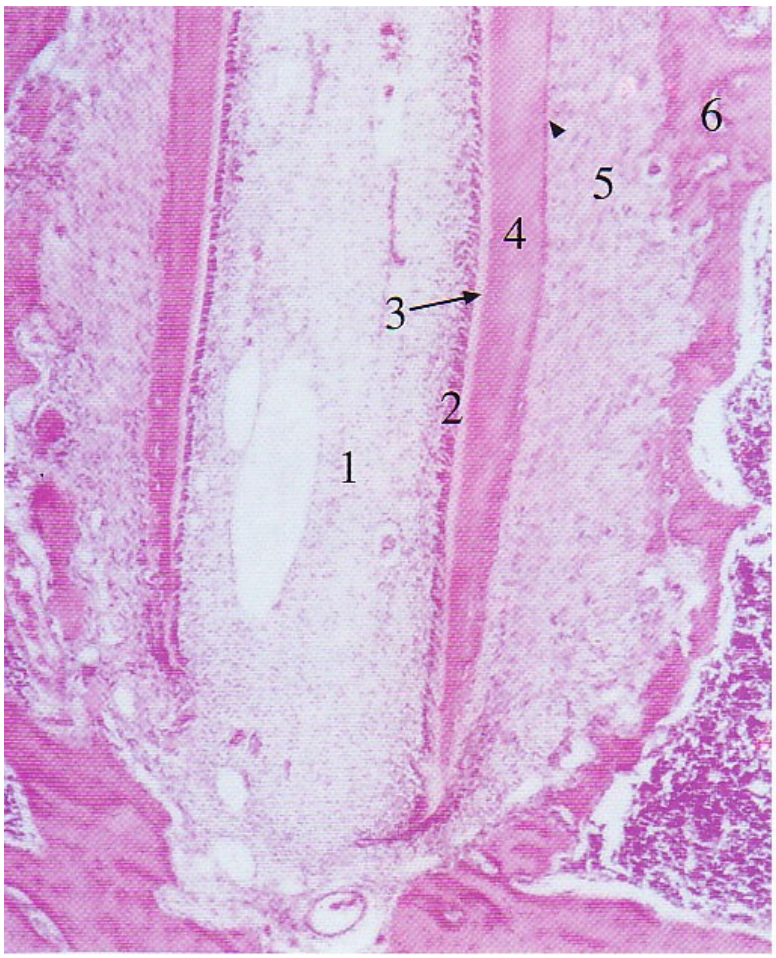

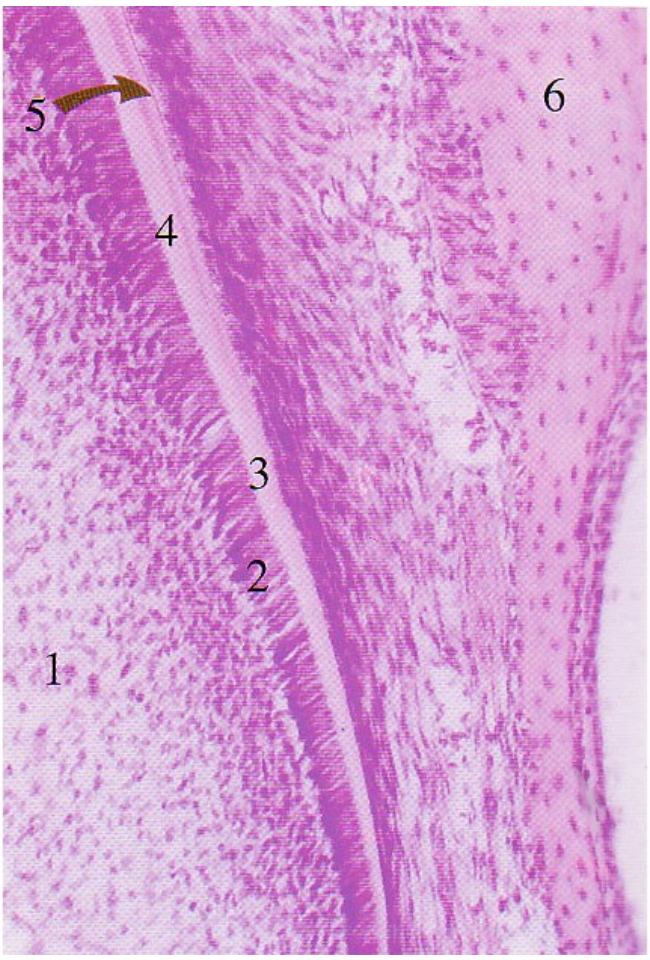

Slide 25
Cementogenesis

1. Pulp
2. Odontoblasts
3. Predentin
4. Dentin
5. Cementum
6. Alveolar bone

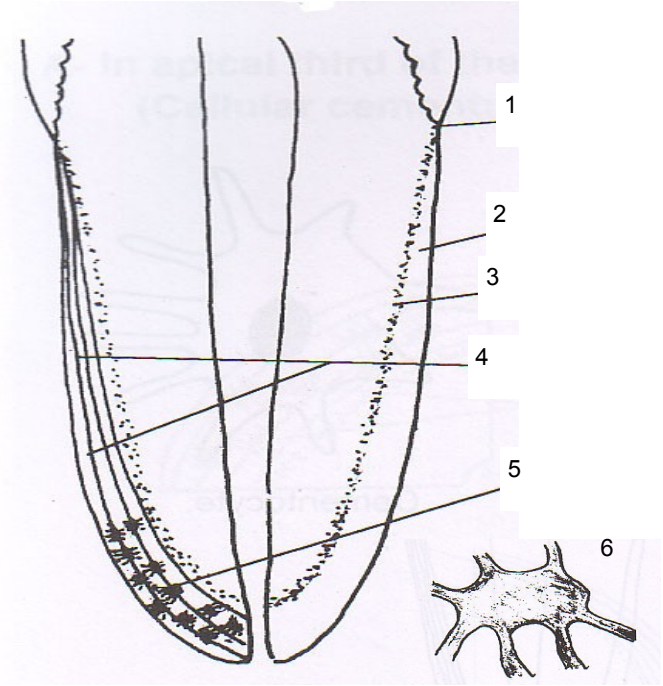

Diagram XI
Longitudinal Ground Section in Cementum

1. Cemento-enamel junction
2. Acellular cementum
3. Tome's granular layer
4. Incremental lines of Saller
5. Cellular cementum
6. Lacuna of cementocyte

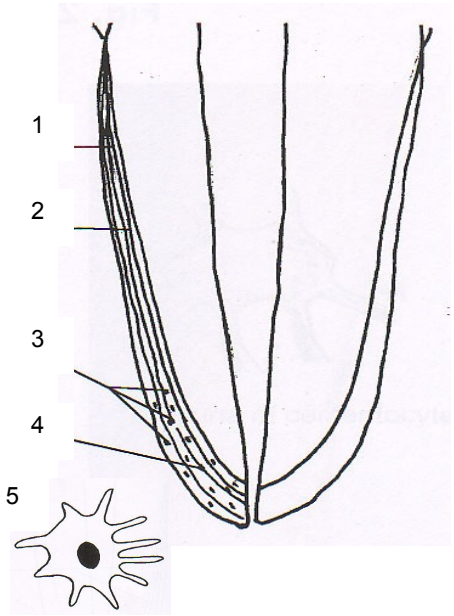

Diagram XII
Longitudinal Decalcified Section in Cementum

1. Acellular cementum
2. Incremental lines of Saller
3. Cementocytes
4. Cellular cementum
5. cementocyte

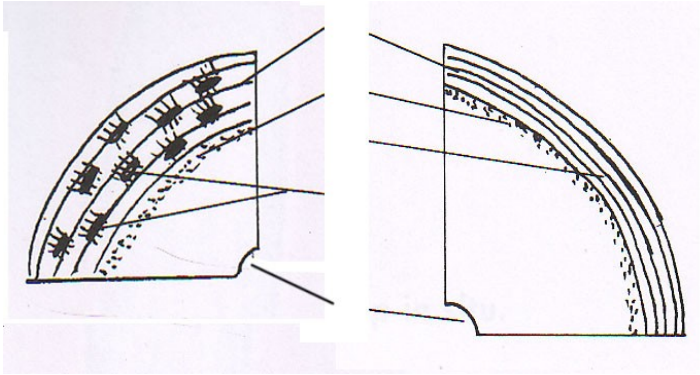

A. Apical third (Cellular cementum)
B. Cervical third (Acellular cementum)

Diagram XIII
Transverse Ground Section in Cementum

1. Incremental lines of Saller
2. Tome's granular layer
3. Acellular cementum
4. Cellular cementum (cementocyte spaces)
5. Pulp space

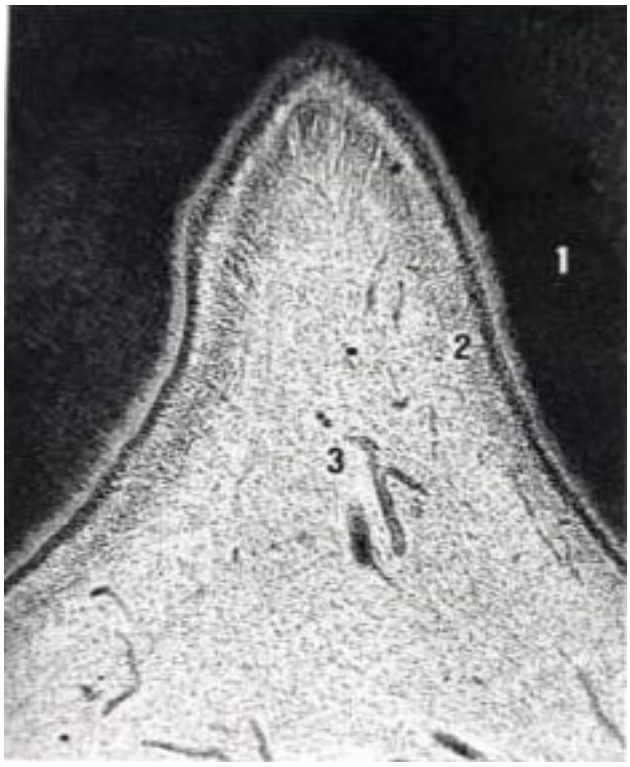

Slide 26
Coronal pulp

Longitudinal section of coronal pulp (H&E X 20)

1. Dentin,
2. Predentin,
3. Pulp tissues

Slide 27
Radicular pulp

Longitudinal section of the radicular pulp (X40, left and X80, right)

A small denticle is evident within the root canal (5) and the anastomosis of blood vessels is evident (7).

1. Dentin
2. Radicular pulp,
3. Periodontal ligament
4. Alveolar bone,
5. Denticle,
6. Secondary dentin,
7. Blood vessles

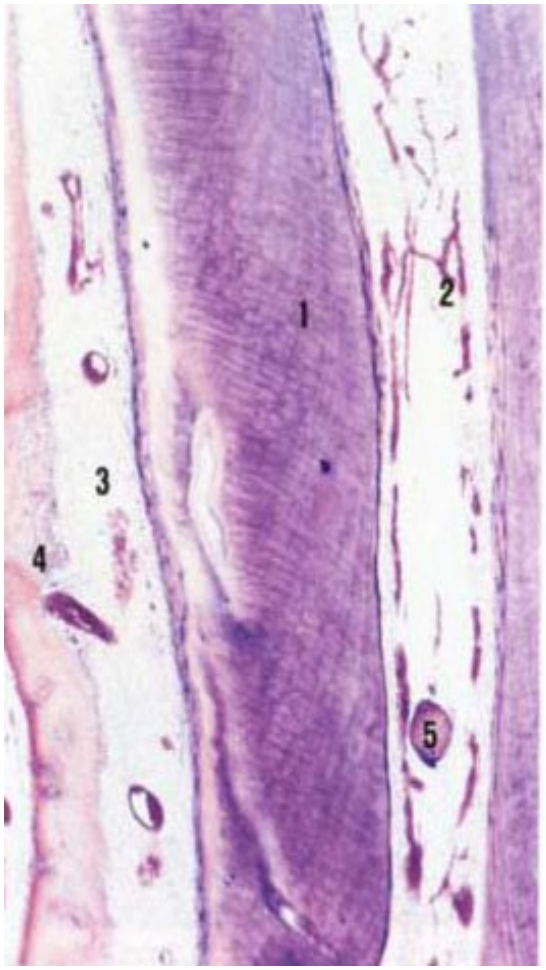

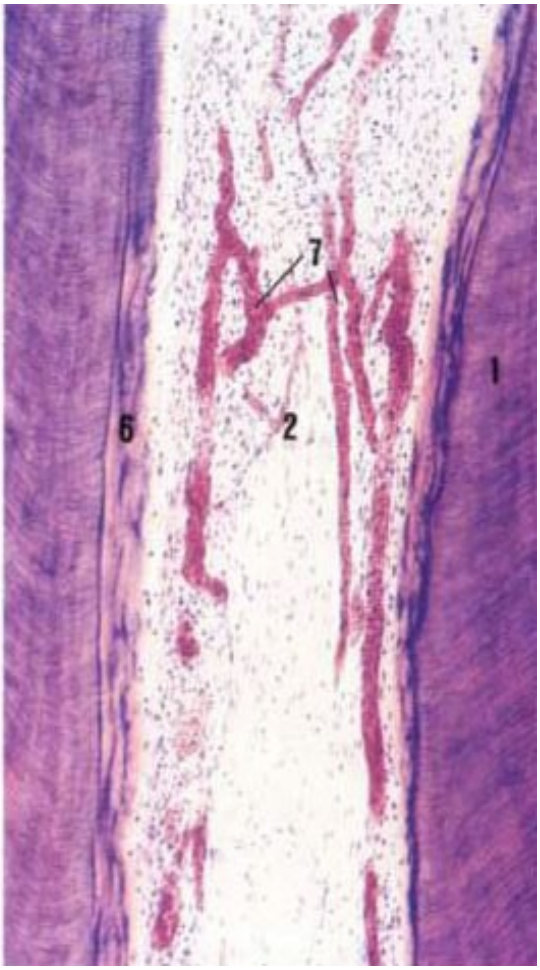

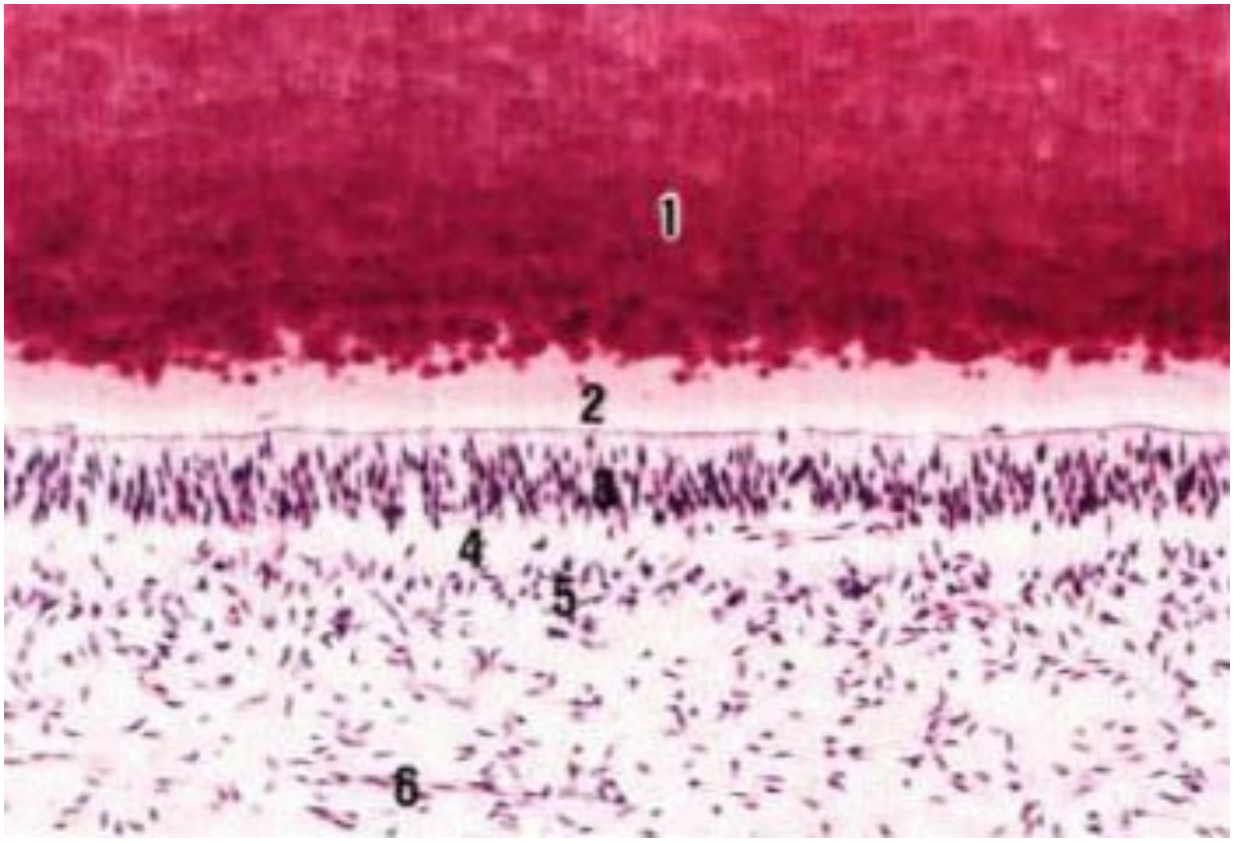

Slide 28
Dentin-Pulp Complex

Longitudinal section of the coronal pulp along the pulpal-dentin border (H&E X180)

1. Dentin
2. Predentin
3. Odontoblastic layer
4. Cell-free zone of Well
5. Cell rich zone
6. Blood vessels

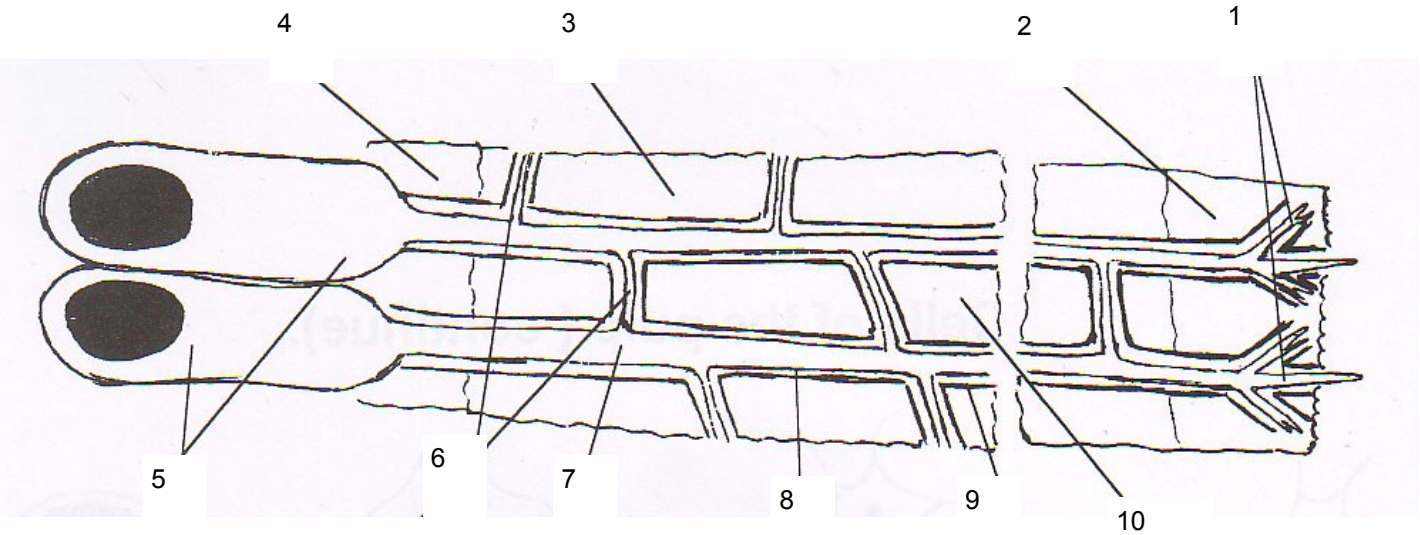

Diagram XIV. Odontoblast

1. Terminal branches
2. Mantle dentin
3. Circumpulpal dentin
4. Predentin
5. Odontoblasts
6. Lateral branche
7. Odontoblastic process
8. Preiodontoblastic space
9. Pretubular dentin
10. Intertubular dentin

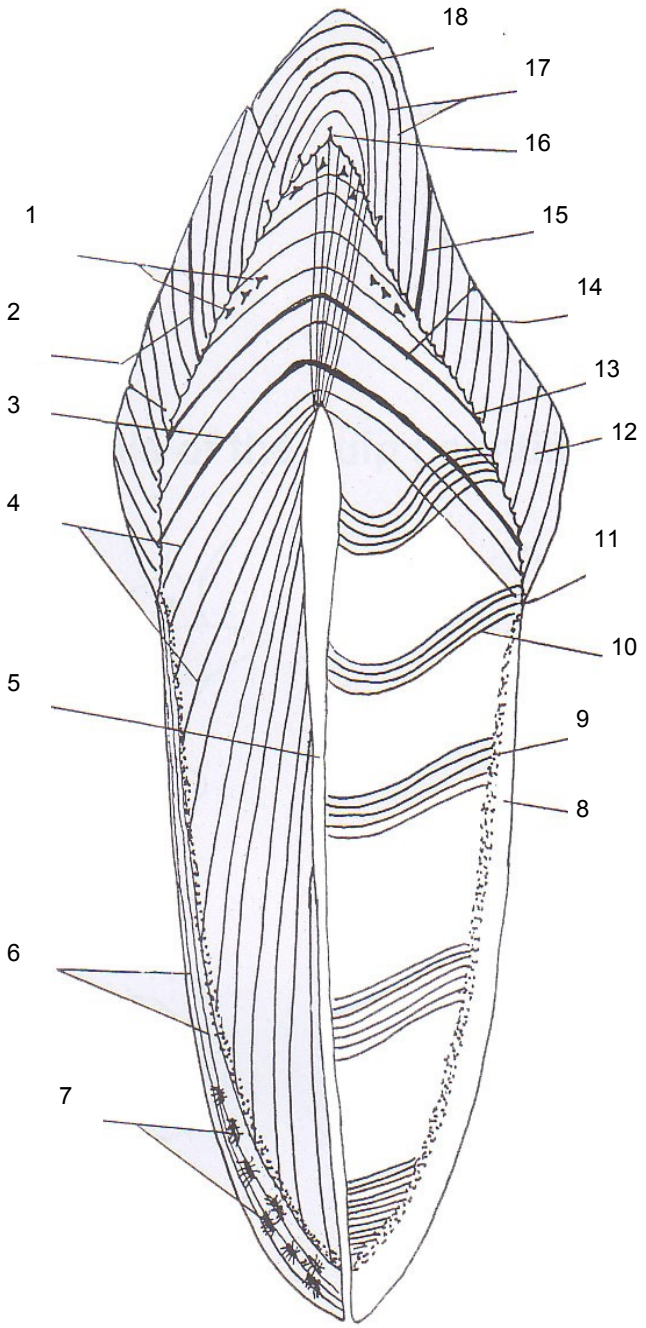

Diagram XVI
Longitudinal Ground Section in Tooth

1. Interglobular dentin space
2. Neonatal line
3. Contour line of Owen
4. Incremental lines of von Ebner
5. Pulp space
6. Incremental lines of Saller
7. Cellular cementum (Lacunae of cementocytes)
8. Acellular cementum
9. Tome's granular layer
10. Dentinal tubules
11. Cemento-enamel junction
12. Postnatal enamel
13. Dentino-enamel junction
14. Enamel lamella
15. Neonatal line
16. Enamel spindle
17. Brown stria of Retizus
18. Prenatal enamel

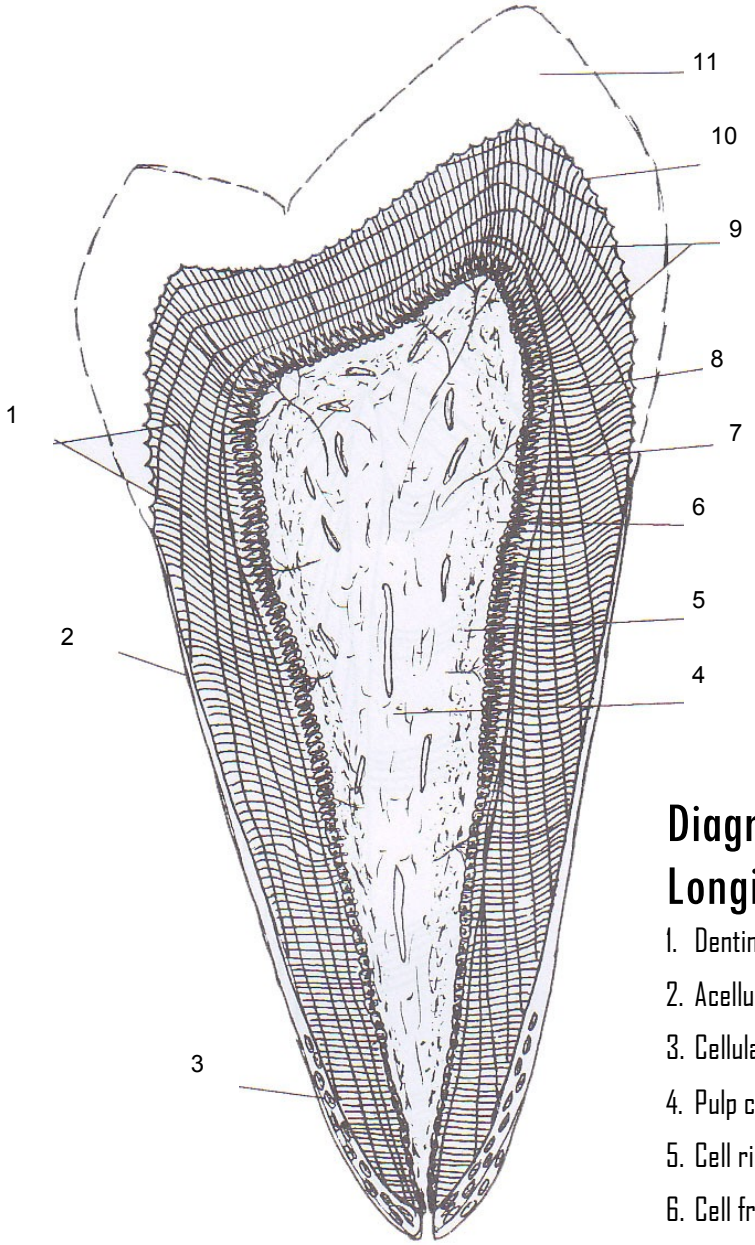

Diagram XVII
Longitudinal Decalcified Section in Tooth

1. Dentinal tubules
2. Acellular cementum
3. Cellular cementum
4. Pulp core
5. Cell rich zone
6. Cell free zone
7. Predentin
8. Odontoblasts
9. Incremental lines of von Ebner
10. Dentino-enamel junction
11. Enamel space

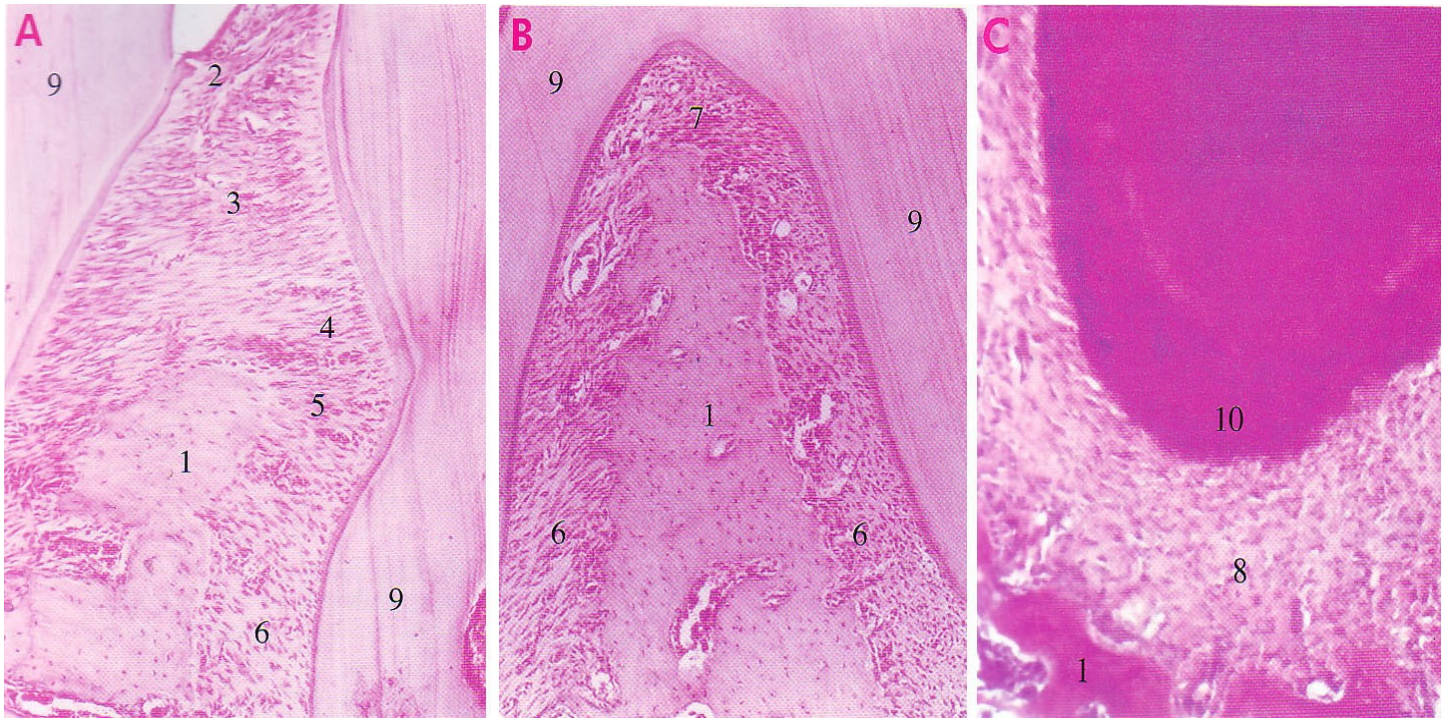

PERIODONTAL LIGAMENTS

Slide 29

Principle Fiber Groups

1. Alveolar bone
2. Gingival fibers
3. Transeptal (interdental) fibers
4. Alveolar crest fibers
5. Horizontal fibers
6. Oblique fibers
7. Interradicular fibers
8. Apical fibers
9. Dentin
10. Cellular cementum

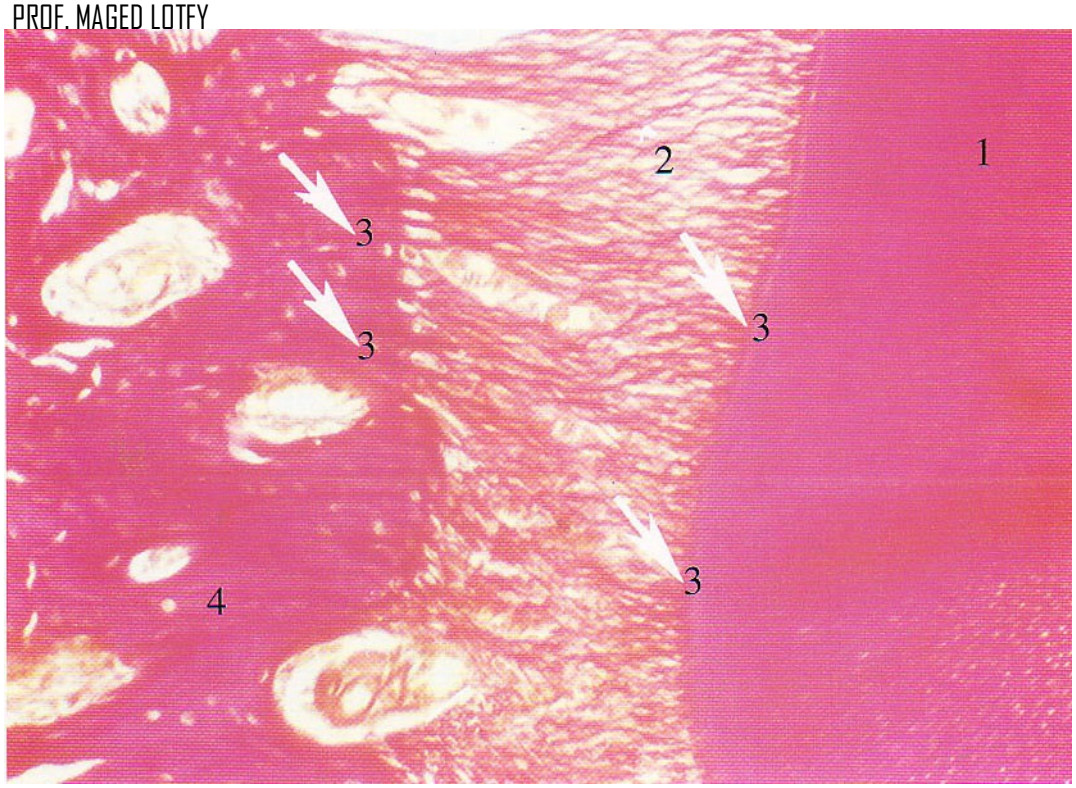

Slide 30
Sharpey's Fibers

1. Dentin,
2. PDL fibers
3. Sharpey's fibers
4. Alveolar bone

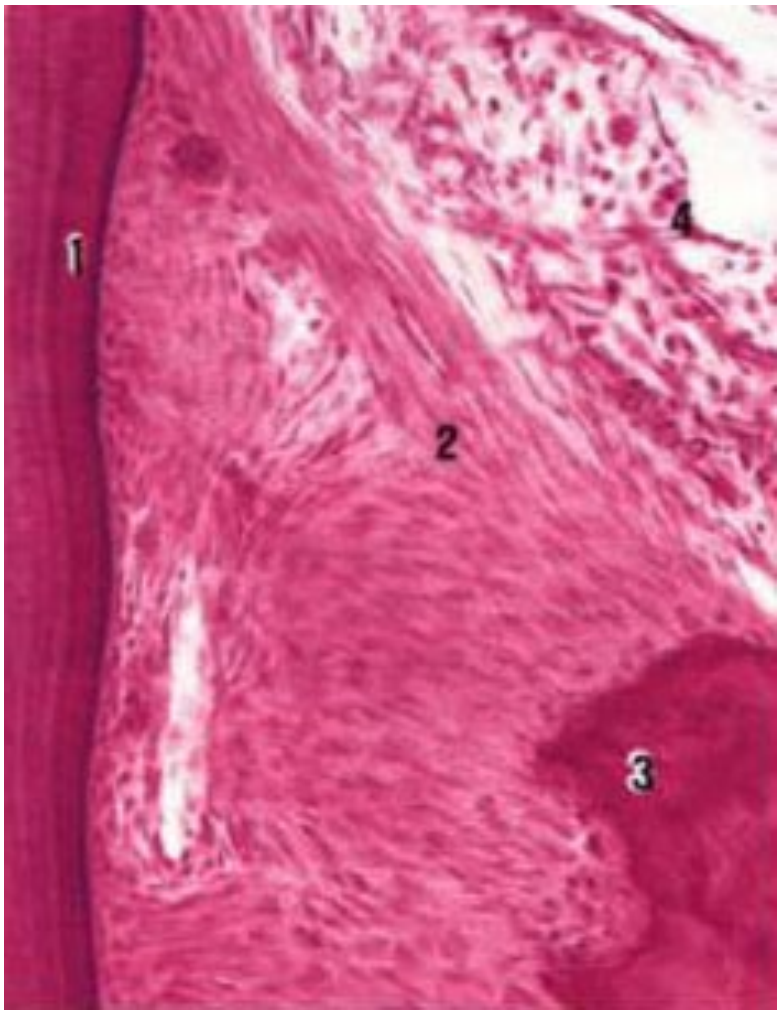

Slide 31

Longitudinal section of the cervical region of the periodontal ligament. (H&E stain X 360)

Two principal dentoalveolar fiber groups can be seen, the alveolar crest group and the cervical horizontal group.

1. Acellular (primary) cementum
2. Alveolar crest principal fibar group
3. Crest of the alveolar bone
4. Lamina propria of the free gingiva
5. Cervical horizontal group

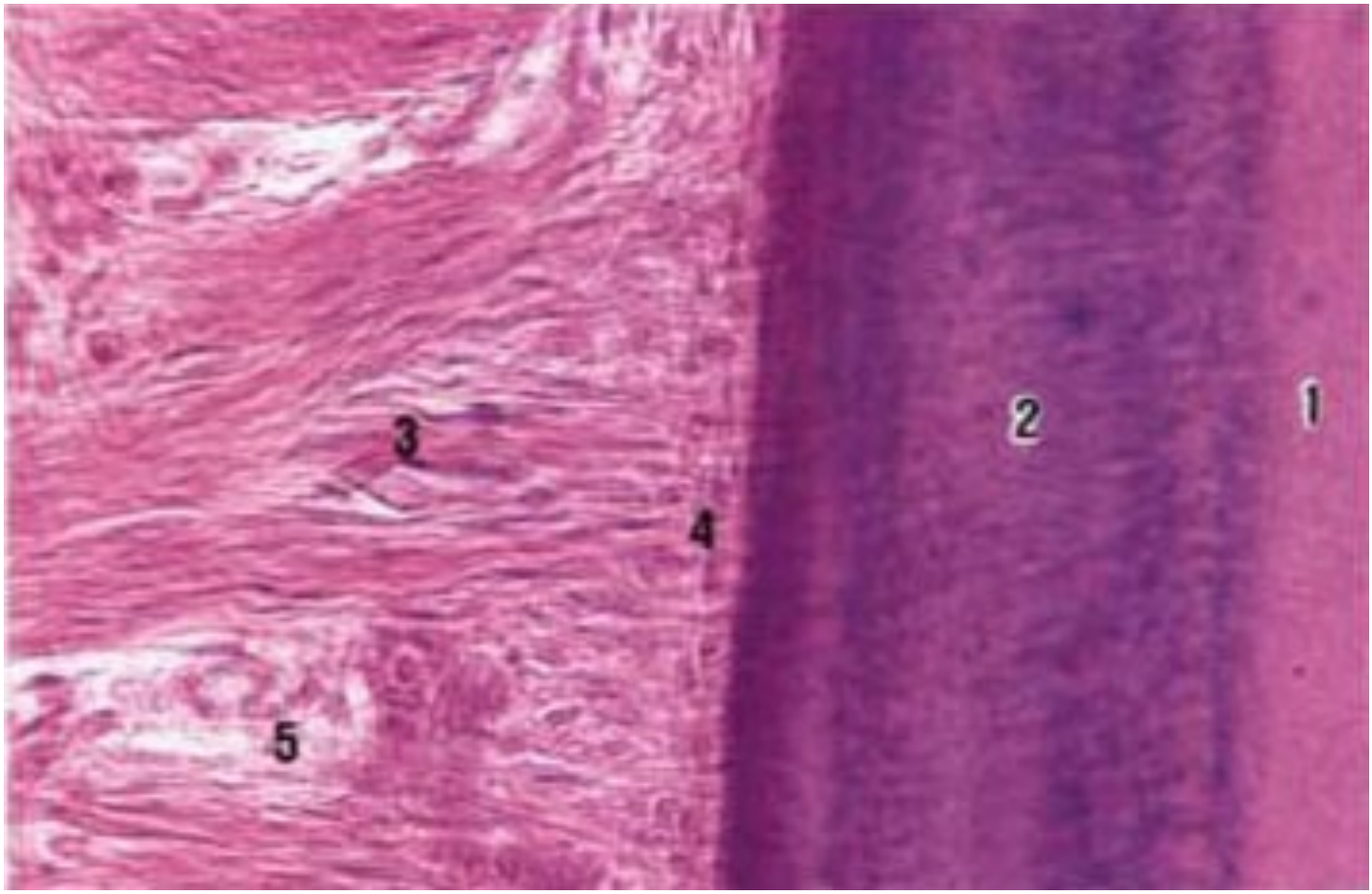

Slide 32
Sharpey's Fibers

Transverse section of the periodontal ligament (H&E stain X540). The terminal ends of the horizontal fibers pass between the cementoblasts and are embedded into the cementum as Sharpey's fibers.

1. Dentin,
2. Acellular cementum,
3. Peridontal ligament,
4. Ceemntoblast,
5. Interstitial spaces.

Slide 33. Interdental Group of PDL

Longitudinal section of crest of the alveolar bone (H&E stain X 50)

The crest of the alveolar bone is crossed by the transseptal fibers extending between two adjacent teeth.

1. Dentine
2. Periodontal ligament
3. Crest of the alveolar bone

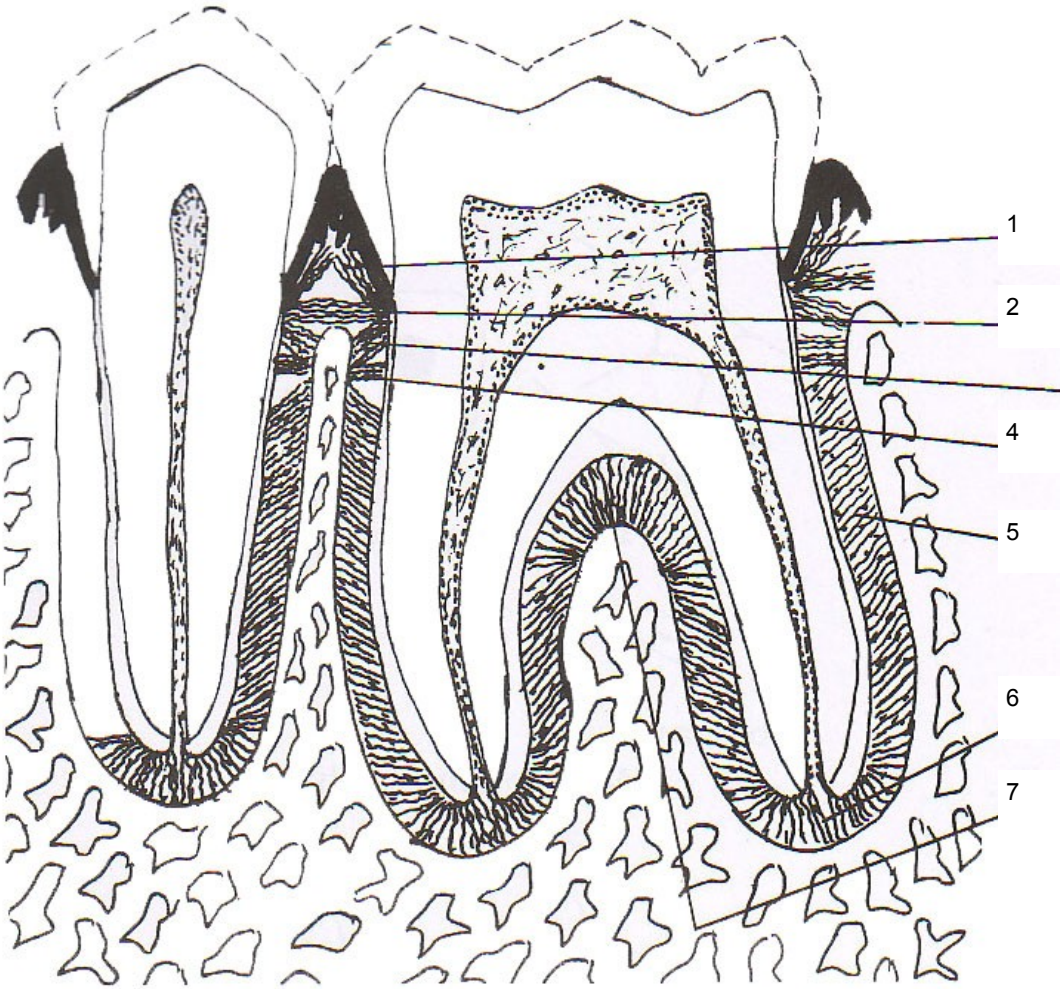

Diagram XX
Principal Fibers of PDL

1. Gingival fibers
2. Interdental group
3. Alveolar crest group
4. Horizontal group
5. Oblique group
6. Apical group
7. Interradicular group

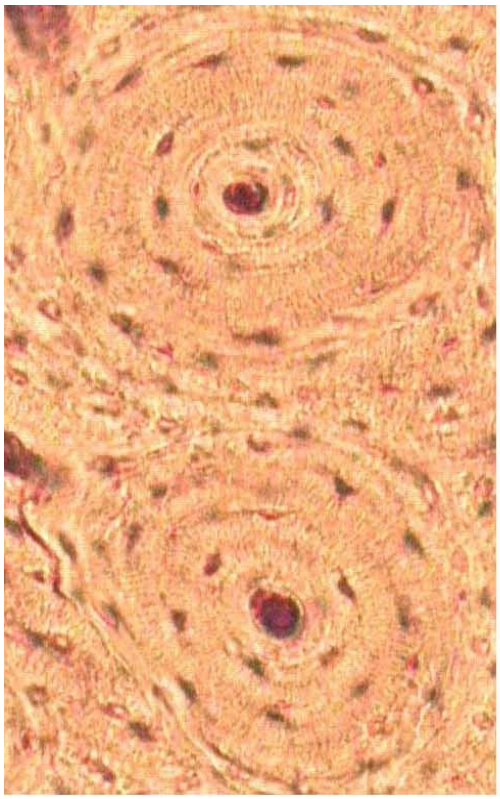
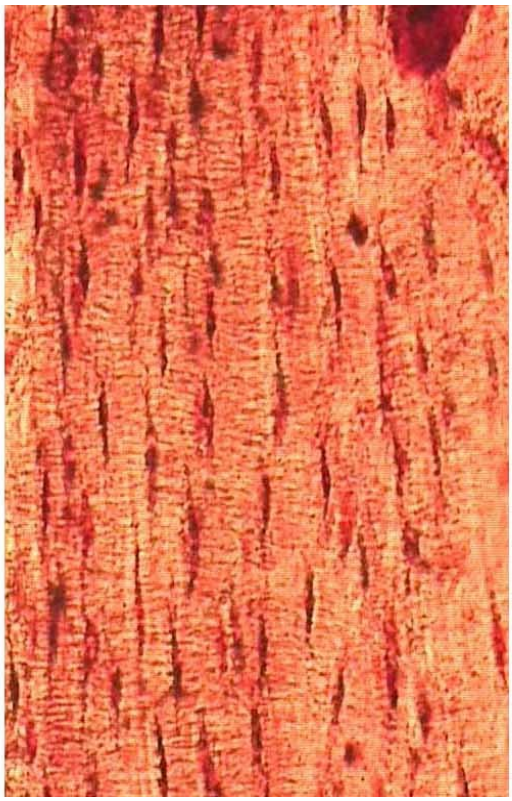


BONE & ALVEOLAR PROCESS

Slide 34

Compact Bone

Compact bone (the osteon) (Left), Lamellar bone (osteocytes in lacunae) (middle)

Lamellar bone showing osteocytes in lacunae and bone canaliculli (high magnification) (right)

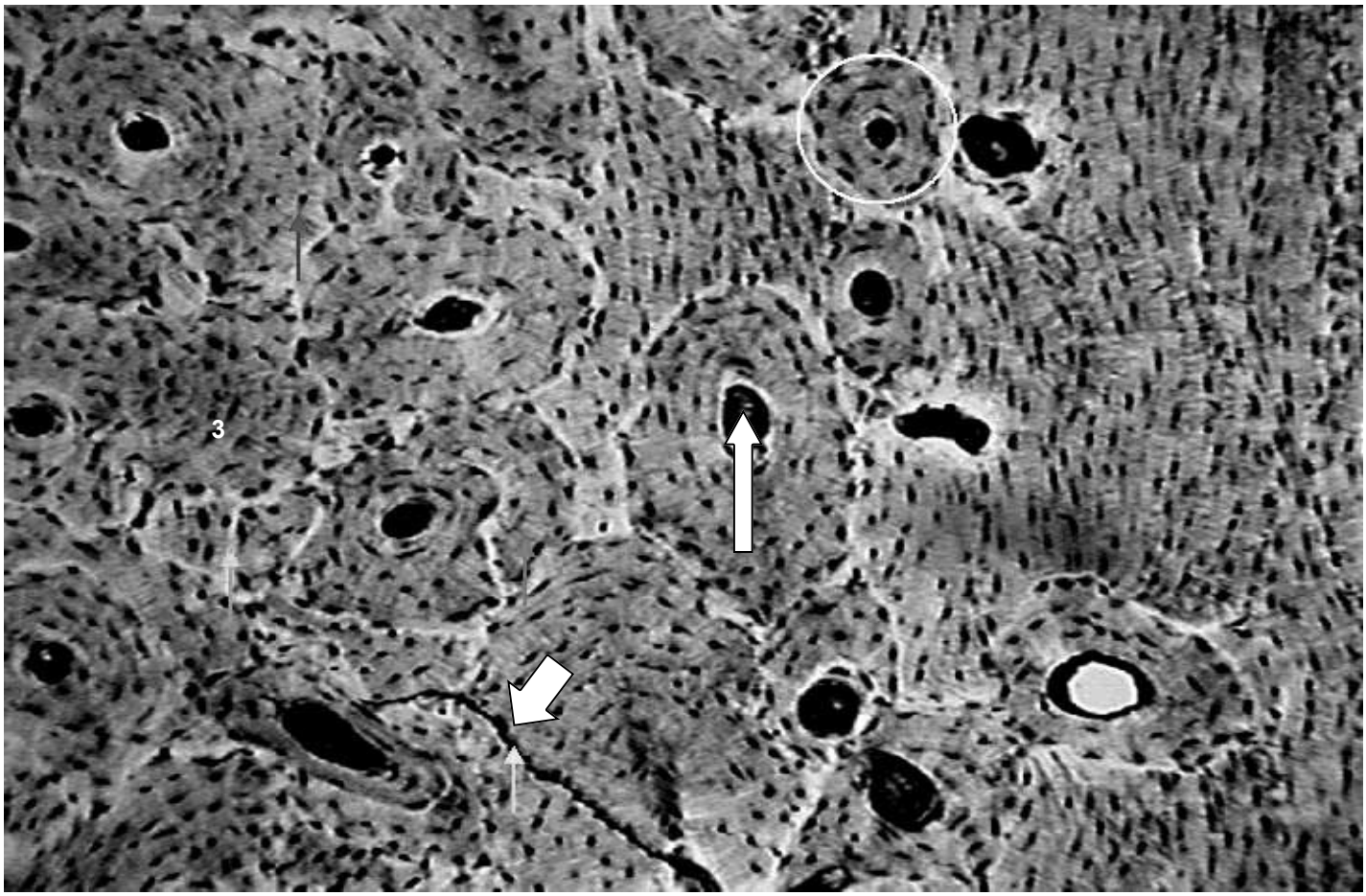

Slide 35
Compact Bone (Ground Section)

1. Osteotone (white circle)
2. Haversian canal (long arrow)
3. Interstitial lamellae
4. Concentric lamellae
5. Volkman's canal (short arrow)

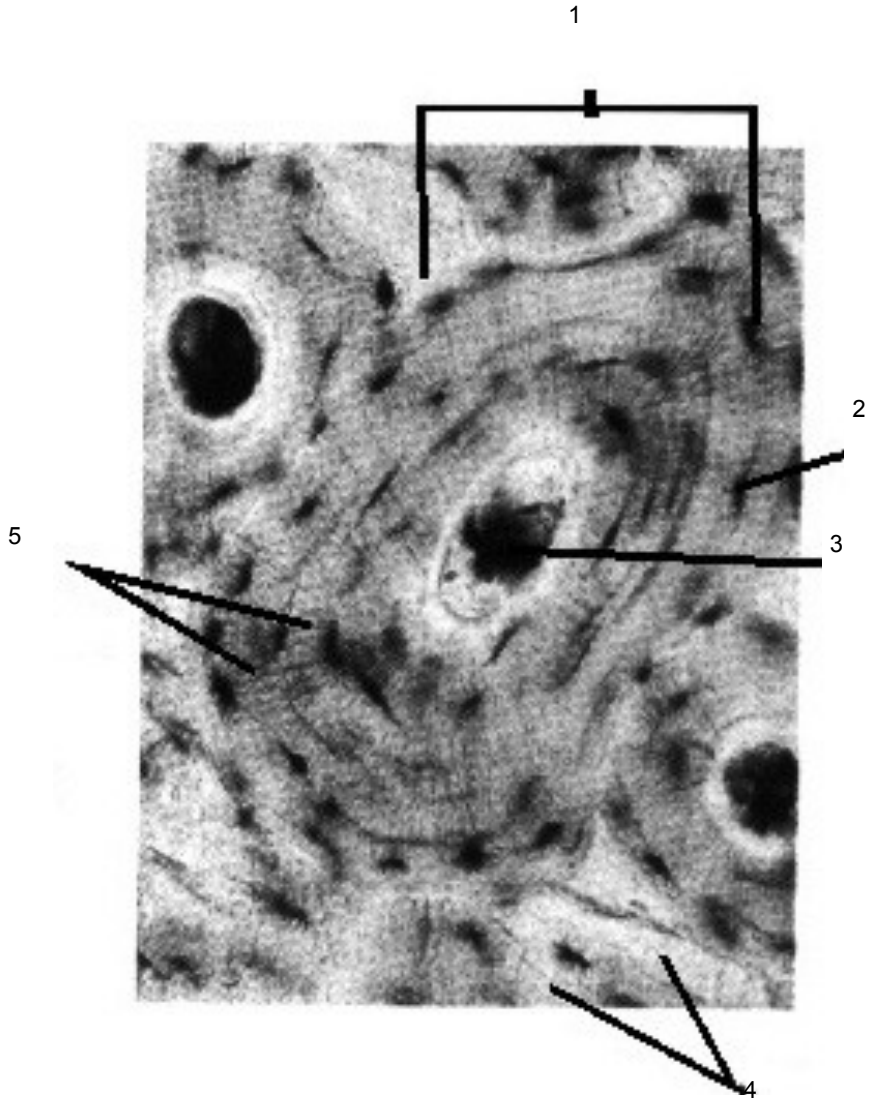

Slide 36.
Compact Bone

The osteon is a unit of structure consisting of concentric lamellae surrounding an Haversian canal.

Lacunae are spaces enclosing the bone cells or osteocytes

Haversian canals run longitudinally through bone allowing passage of small blood vessels

Interstitial lamellae are non-circular remnants left behind from former osteons when new osteons replace them.

The tiny hairs are small canaliculi which allow extensions of the osteocytes to reach out and obtain nutrient and even form contacts with one another.

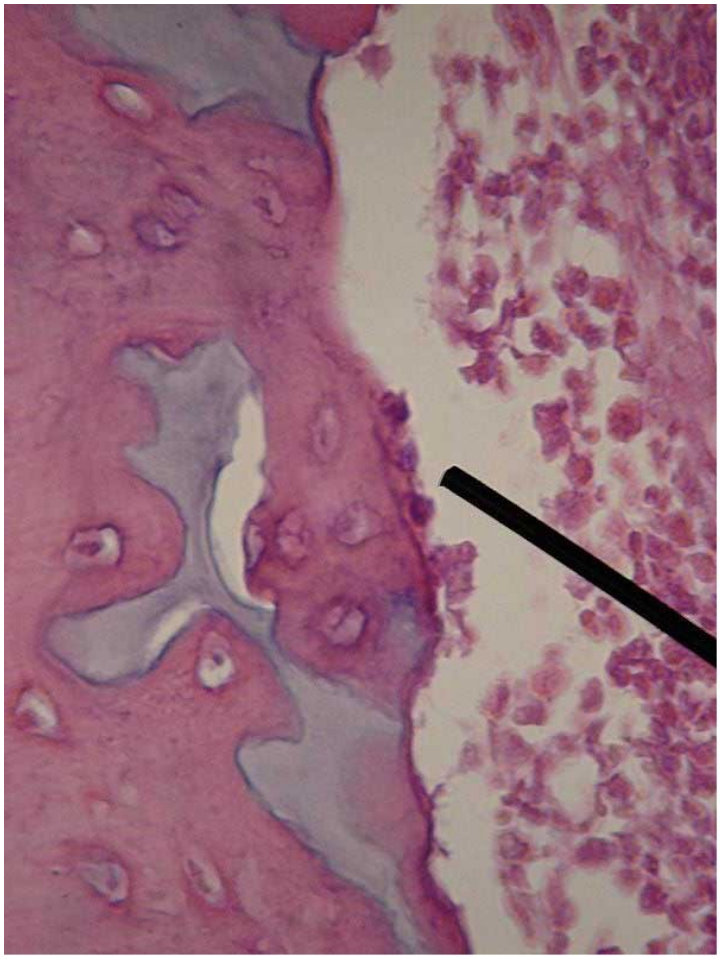

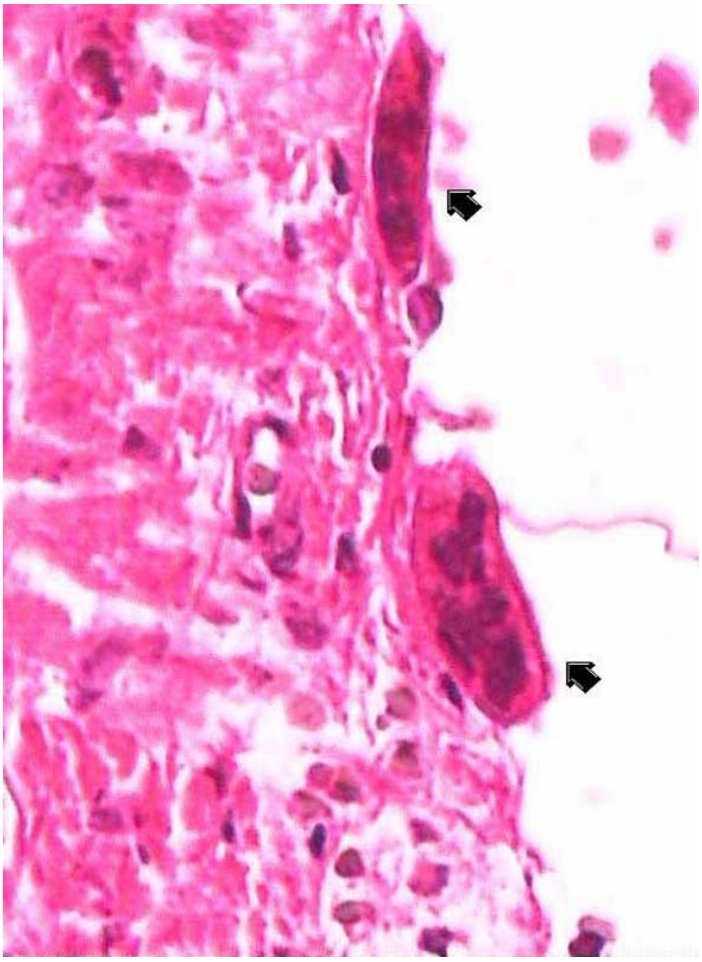

Slide 37
Ostoblast (Left) and Osteoclast (Right)

Osteoblast is oval or columnar in shape and has eccentric nucleus and basophilic cyto-plasm

Osteoclasts are gaint cells with 20-100 micron, multinucleated (30 nucleus) and lie in a bay-like depression called Howship's lacunae on the surface of bone.

The main function of osteoclast is bone resorption. The cell membrane adjacent to the bone has a ruffled border and surrounded by a clear zone of cytoplasm. Cytoplasm is eosinophilic.

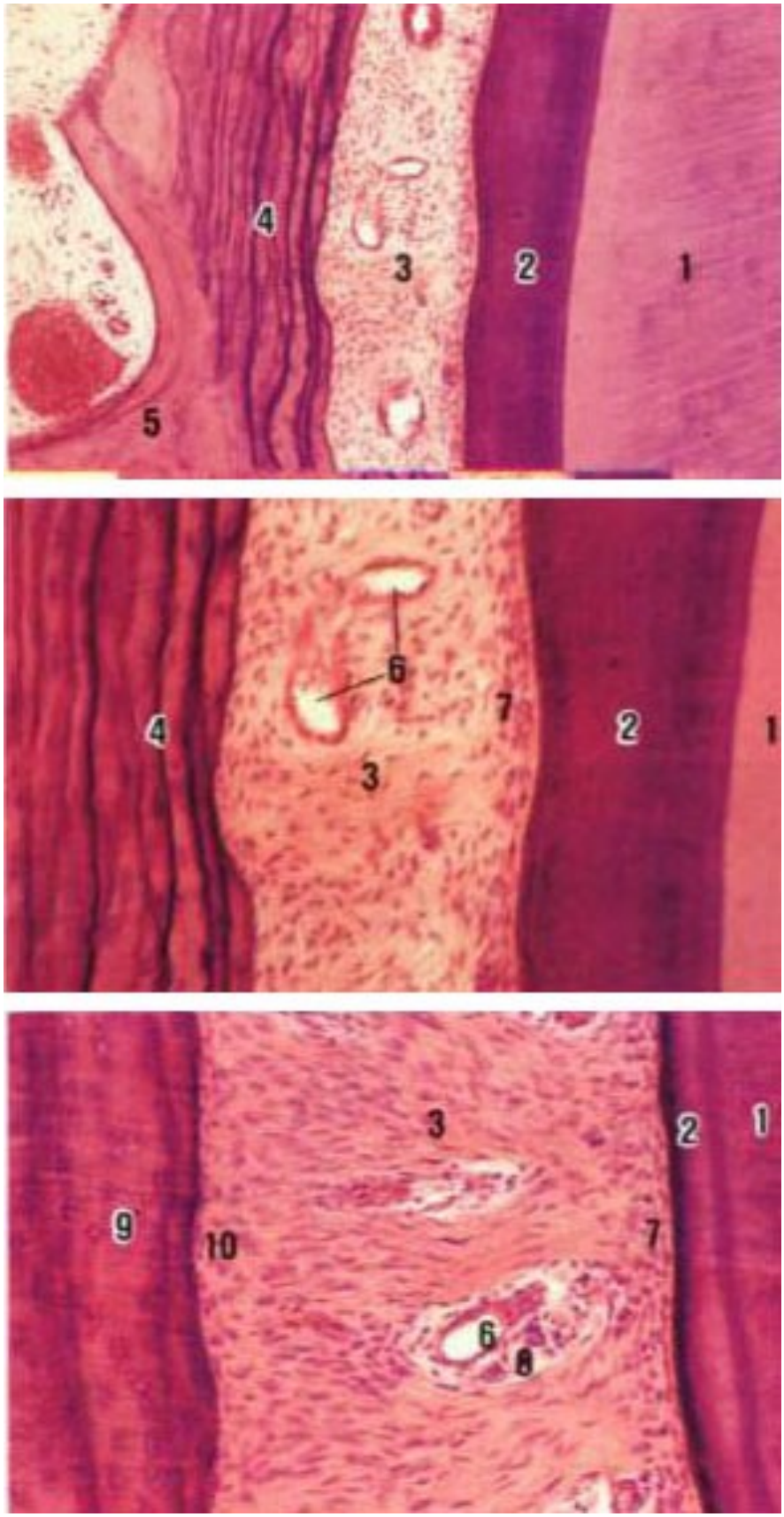

Slide 38
The Alveolar Bone

Transverse section of midroot region of a tooth (upper & lower). Magnified section (middle).

Alveolar bone proper consists of lamellar bone and may contain a Haversian system. Blood vessels are located within the interstitial spaces. Osteoblasts and cementoblasts line the surface of the bone and the cementum respectively. A blood vessel and a nerve lie within the loose connective tissue of an interstitial space.

1. Dentin
2. Cementum
3. Periodontal ligament
4. Bundle bone
5. Lamellar bone
6. Blood vessel
7. Cementoblast
8. Nerve fiber bundle
9. Alveolar bone
10. osteoblast

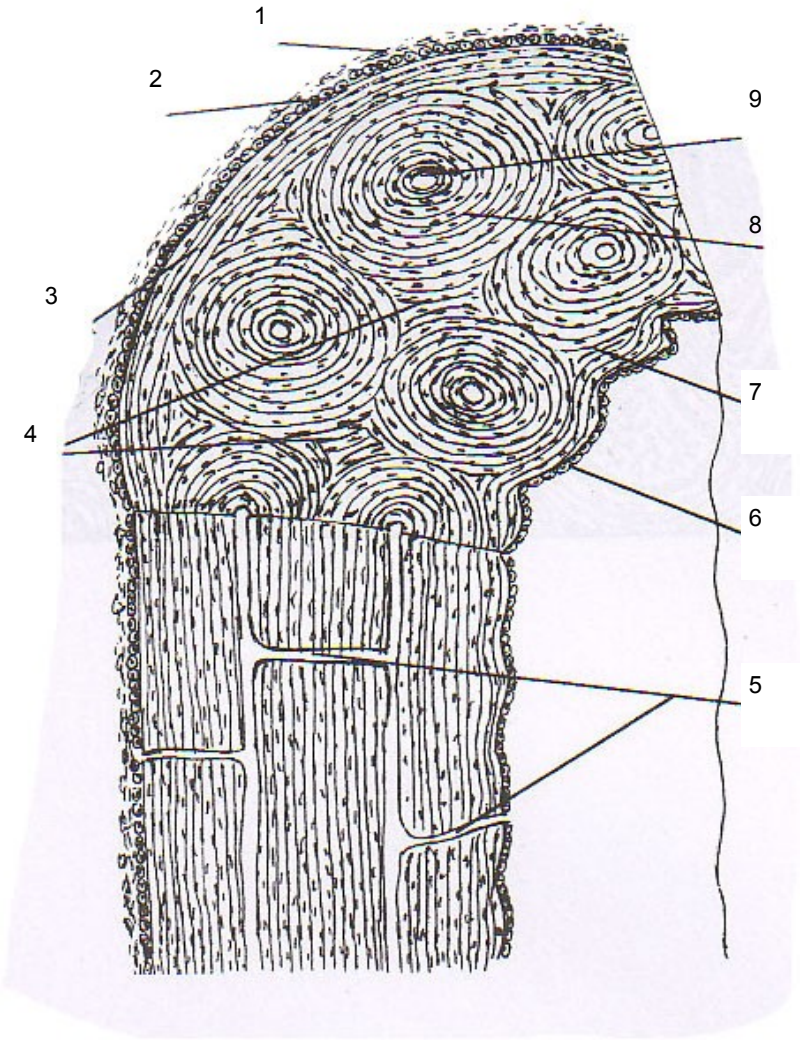

Diagram XXI
Decalcified Section in Compact Bone

1. Periosteum, outer fibrous layer.
2. Periosteum, osteogenic layer
3. Outer circumferential lamellae
4. Interstitial lamellae
5. Volkmann's canal
6. Endosteum
7. Inner circumferential lamellae
8. Haversian lamellae
9. Haversian canal

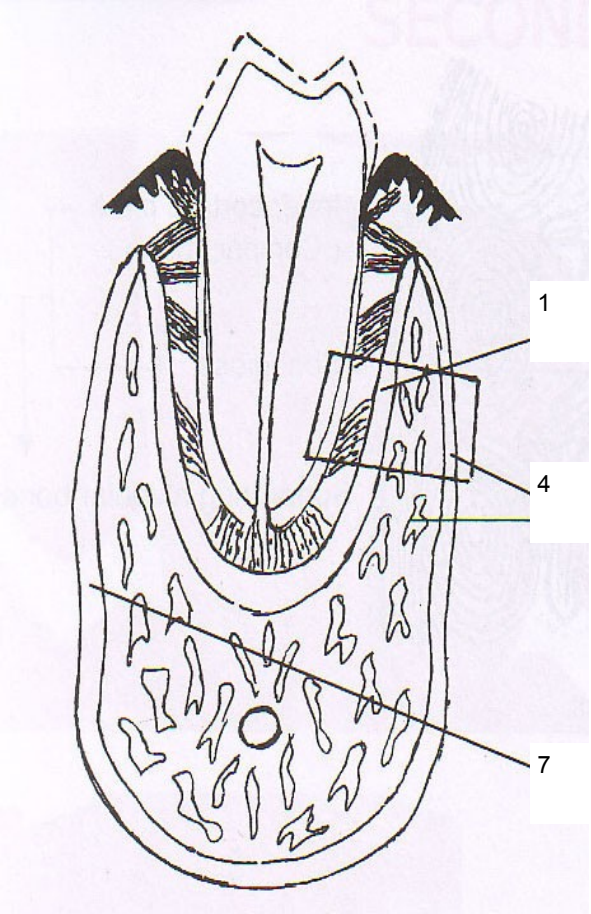

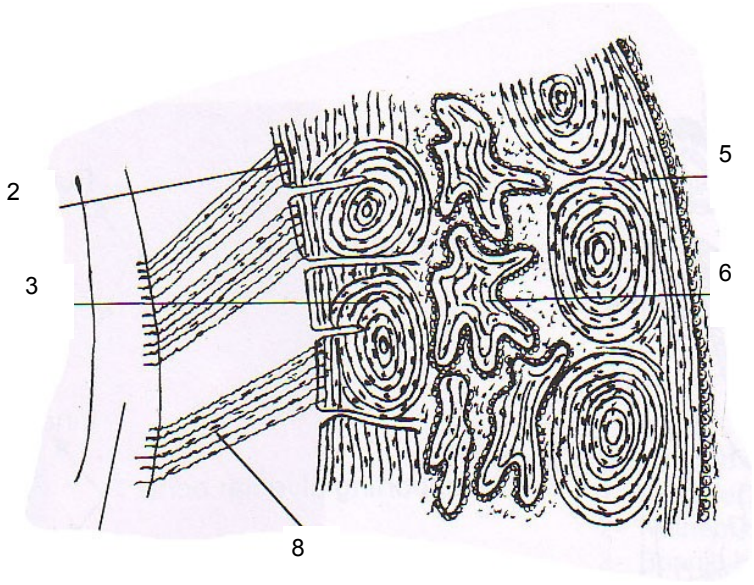

Diagram XXIIV
Macroanatomy of Alveolar Process

1.
2. Alveolar bone proper
3. Bundle bone
4. Lamellar bone
5. Supporting alveolar bone
6. Inner cortical plate (compact bone)
7. Spongiosa
8. Outer cortical plate (compact bone)
9. Periodontal ligament

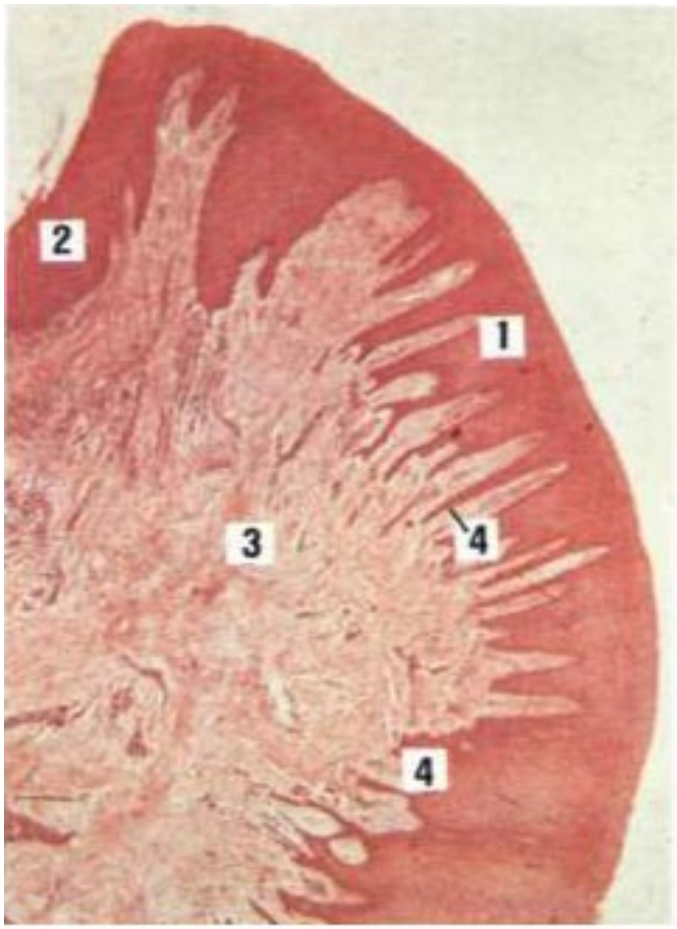

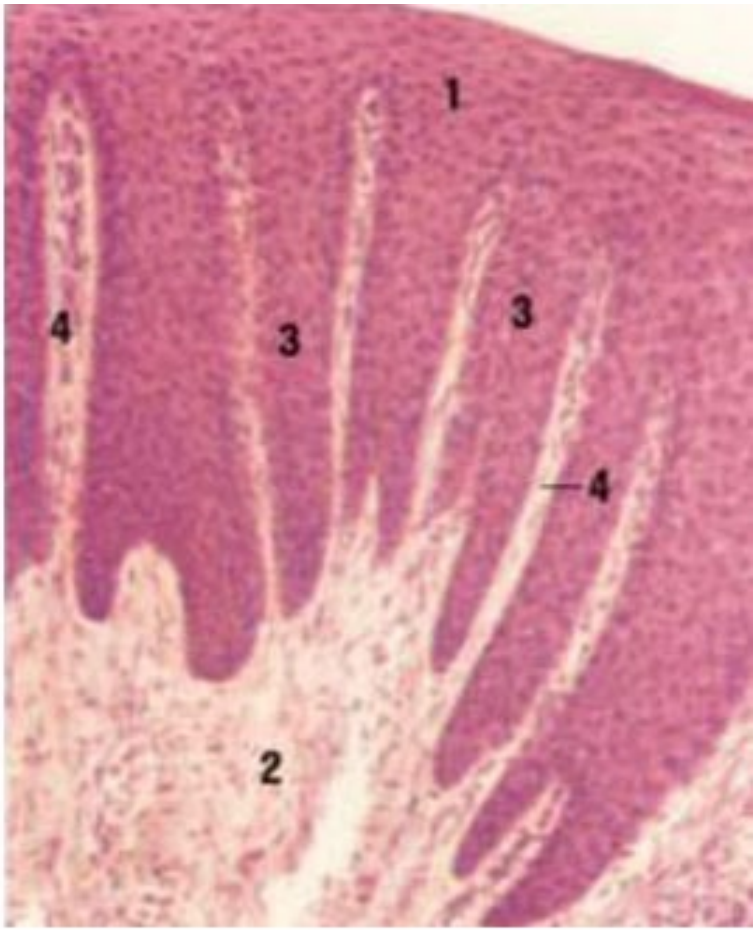

ORAL MUCOSA

Slide 39

Gingival Epithelium

The numerous long slender connective tissue papillae interdigitate with epithelial ridges to resist shear forces on the free and attached gingiva.

(left) 1. gingival epithelium, 2. gingival sulculus, 3. gingival lamina properia, 4. connective tissue papilla.

The gingival epithelium ios parakeratinzed with numerous epithelial ridges interlocking with long slender connective tissue papilla.

(right)

1. Gingival epithelium
2. Lamina properia
3. Epithelial ridges
4. Connective tissue papillae

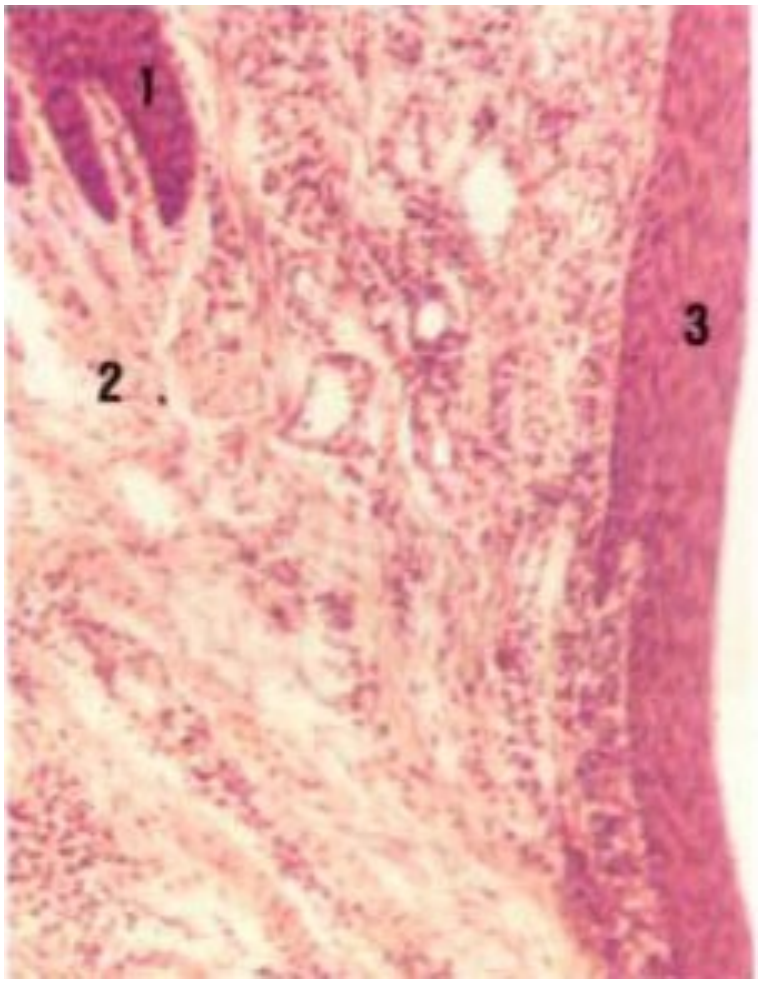

Slide 40
Sulcular Epithelium

The epithelium of the gingival sulcus and the junctional epithelium are nonkeratinized.

1. Marginal epithelium
2. Lamina properia
3. Gingival sulcular epithelium

Slide 41
Gingival Attachment

Demineralized longitudinal section of the cervical margin of a tooth. The junctional epithelium is thinner with a smooth intercace with the gingival lamina proporia. The enamel space is bordered by the junction epithelium and the dentin.

1. Dentin,
2. Enamel space,
3. Junctional epithelium,
4. Lamina propria,
5. Cementum

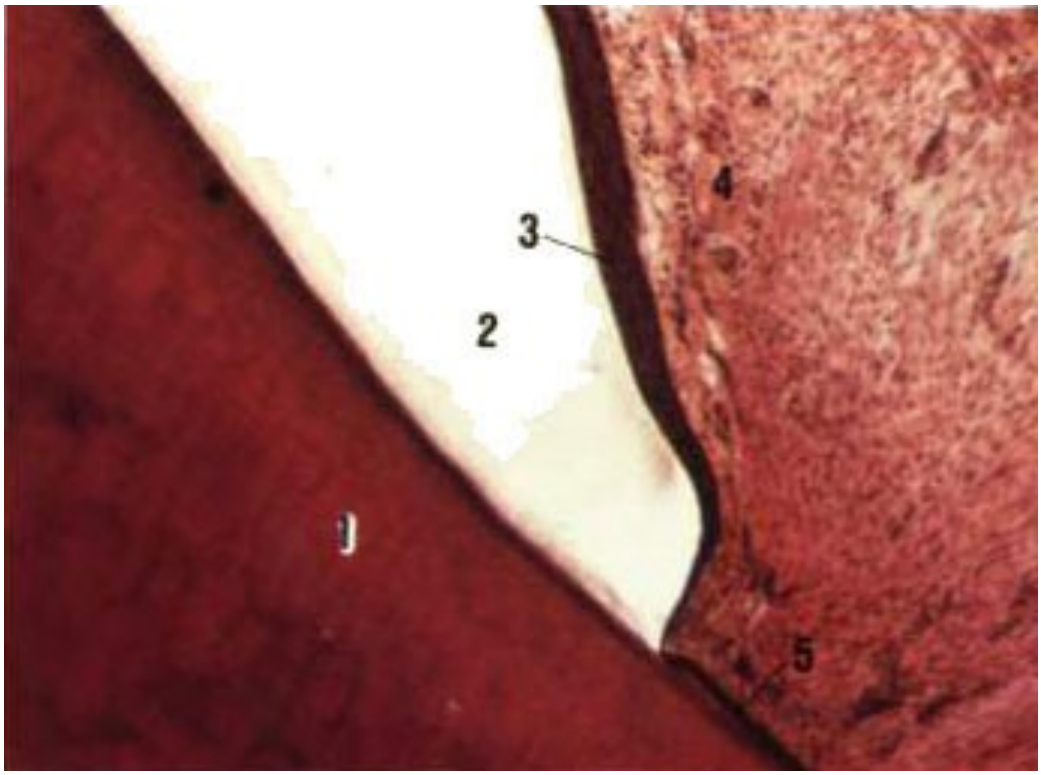

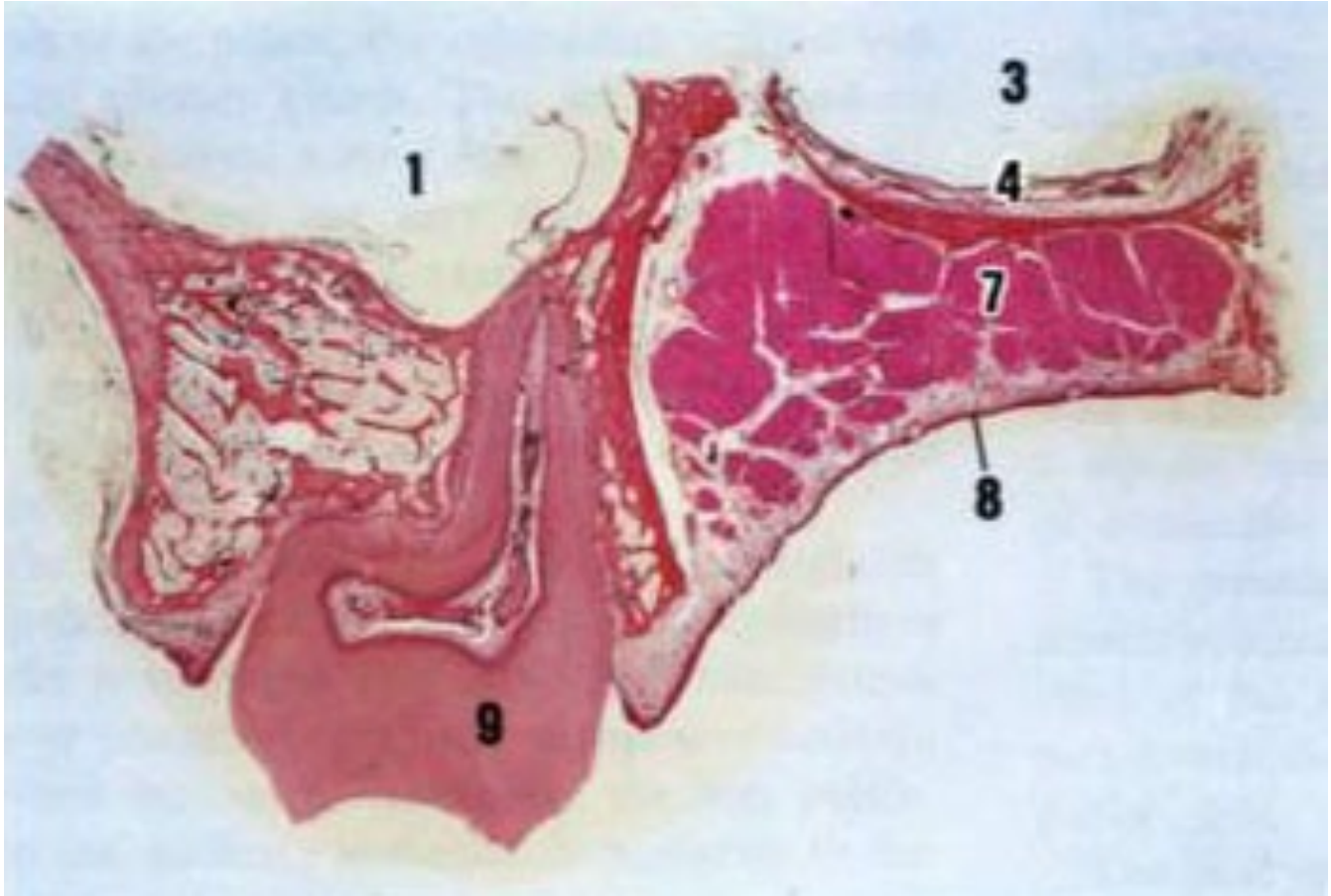

Slide 42
Frontal Section of Hard Palate

1- Maxillary sinus,

3- Nasal cavity,

4- Nasal mucosa,

7- Palatine mucous glands,

9. Maxillary first molar

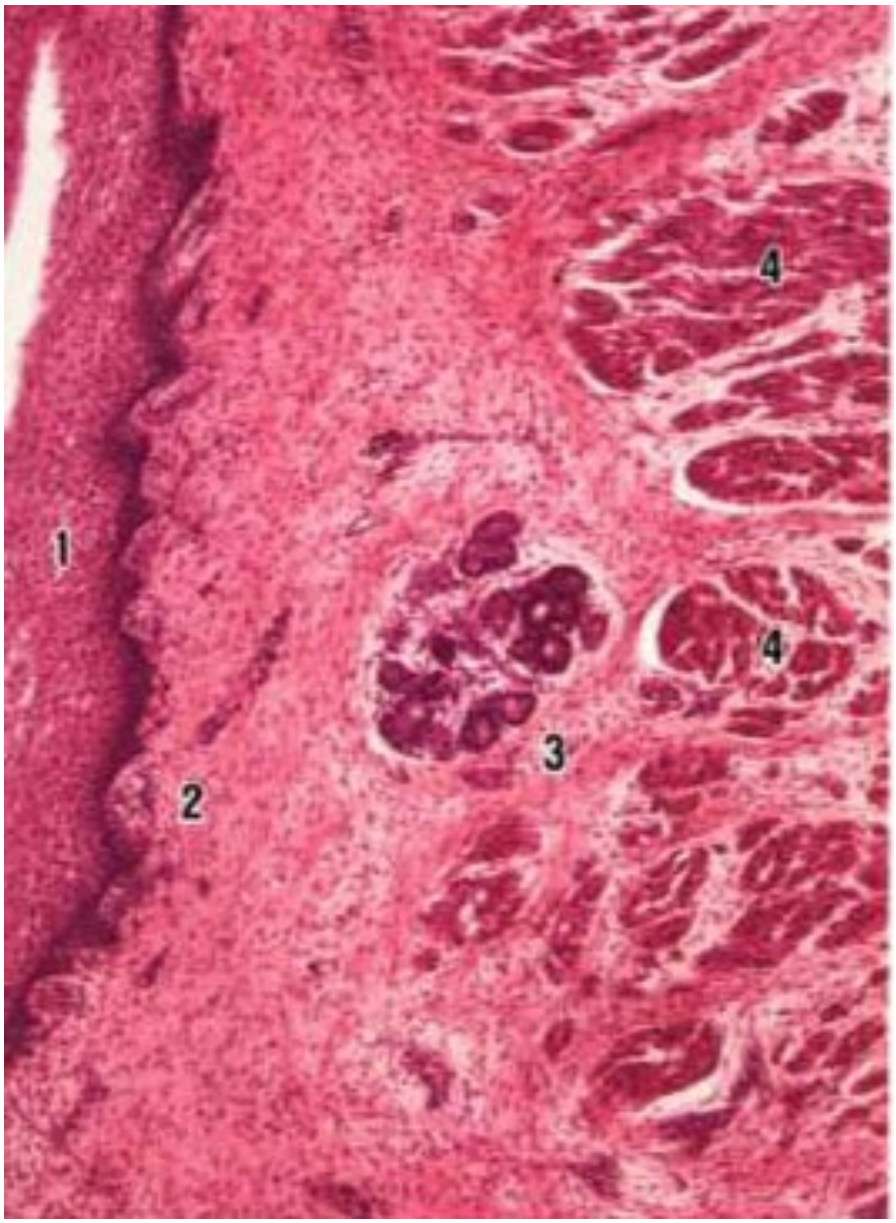

Slide 43
Frontal Section of Buccal Mucosa

1. Stratified squamous epithelium of buccal mucosa
2. Lamina propria of oral mucosa
3. Buccal sermucous gland
4. Buccinators muscle
5. Epidermis
6. Hair
7. Sebaceous gland associated with hair follicle

Slide 44
Sagittal Section of Lip

1-3. Oral mucous membrane,

1-2. vermillion border (mucocutaneous junction),

2-4 Thin skin,

5. labial seromucous glands,

6. Orbicularis oris muscle,

7. Hair follicles

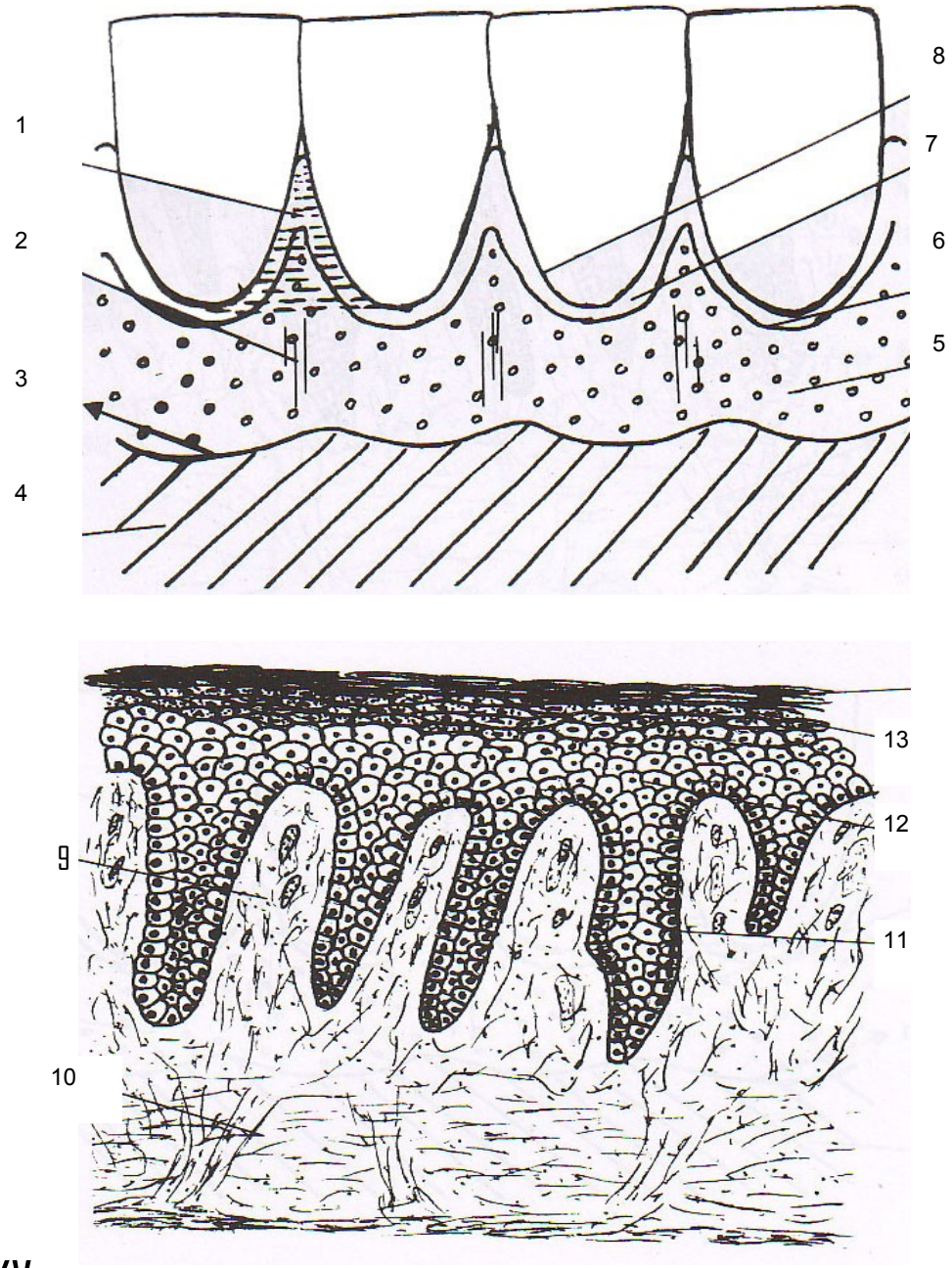

Diagram XXV

Macroanatomy (upper) and Microanatomy (lower) of Gingiva

1. Interdental papillae
2. Interdental groove
3. Mucogingival junction
4. Alveolar bone
5. Attached gingiva
6. Free gingival groove
7. Free gingiva
8. Marginal gingiva
9. Papillary layer
10. Reticular layer
11. Basal cell layer
12. Spinous cell layer
13. Granular cell layer
14. Cornified layer

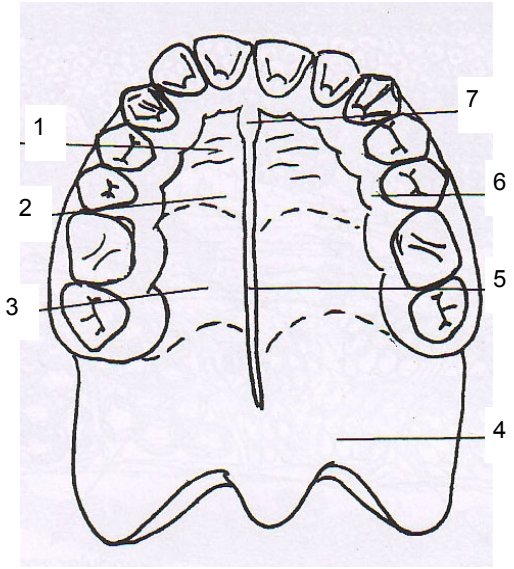

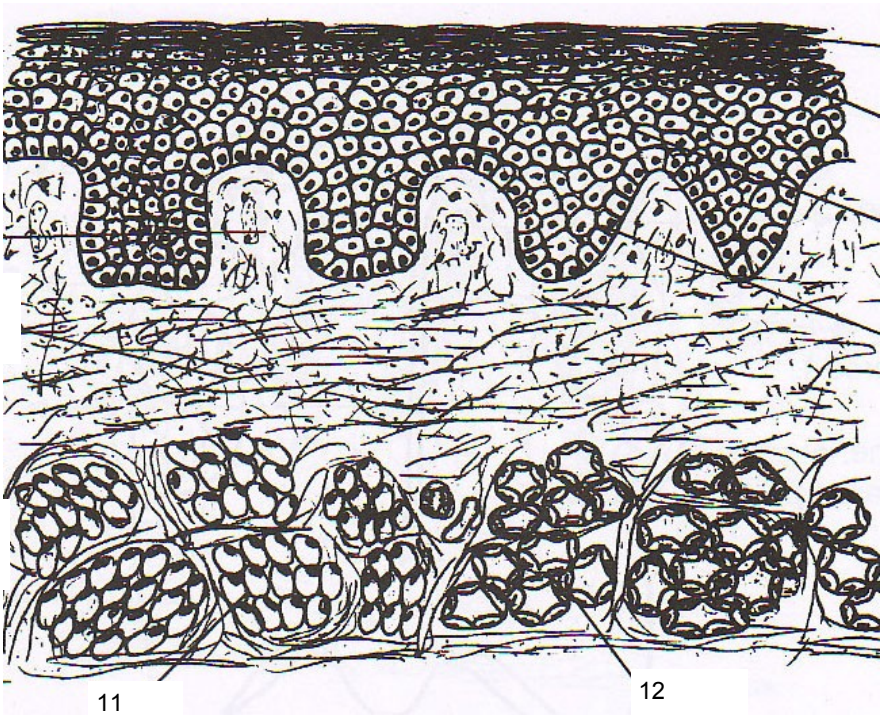

Diagram XXVI
Macroanatomy (upper) and Microanatomy (lower) of Hard Palate

1. Palatine rugae
2. Fatty zone (antero-lateral area)
3. Glandular zone (postero-lateral area)
4. Soft palate
5. Median palatine raphe
6. Palatine gingiva
7. Incisive papillae
8. Papillary layer
9. Reticular layer
10. Submucosa
11. Fatty zone
12. Glandular zone
13. Basal cell layer
14. Spinous layer
15. Granular layer
16. Cornified layer

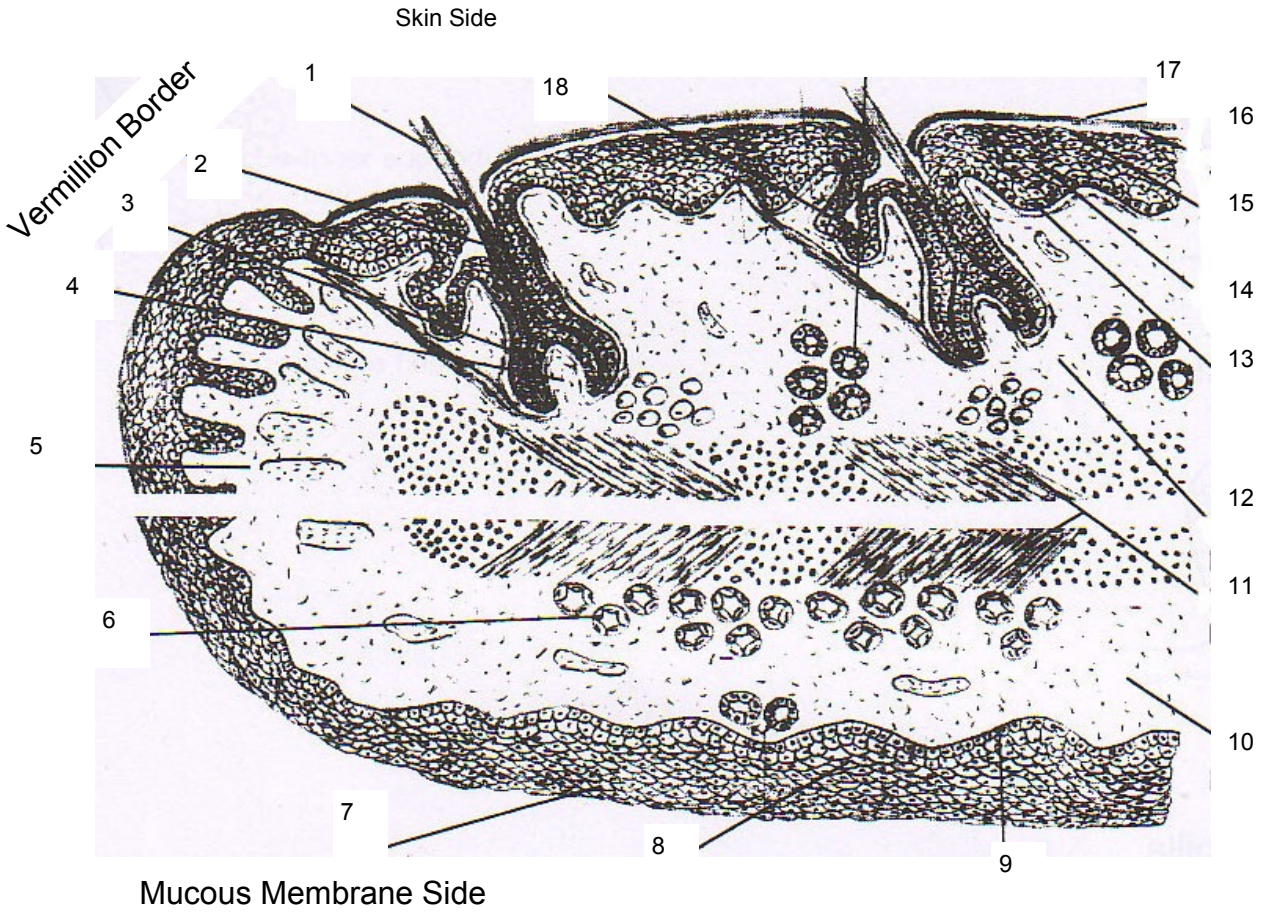

Diagram XXVI
Sagittal Section of Lip

1. Hair shaft
2. Hair root
3. Hair pulp
4. Hair papilla
5. Capillary loops
6. Submucosa (mucous gland)
7. Stratum superficial
8. Stratum intermedium
9. Stratum basal
10. Lamina properia
11. Muscle of the lip
12. Dermis
13. Bsal cell layer
14. Spinous cell layer
15. Granular cell layer
16. Stratum lucidum
17. Cornified layer
18. Sweat gland
19. Sebaceous gland

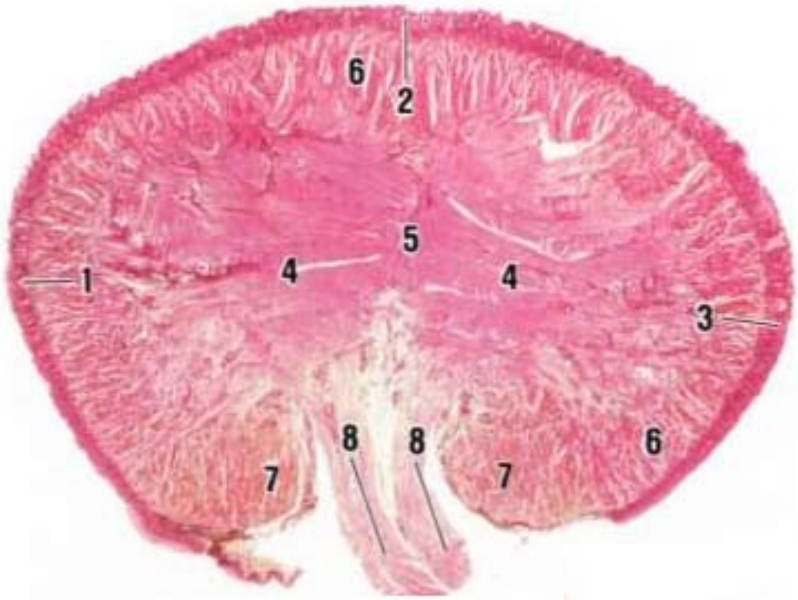

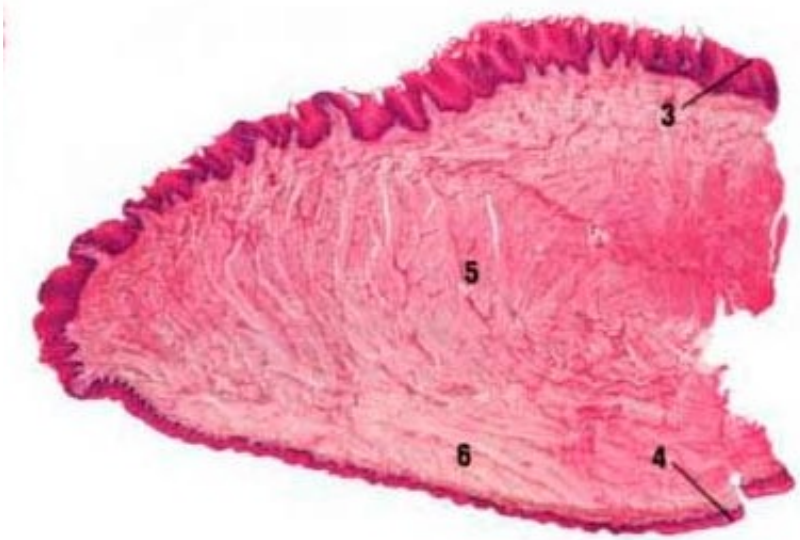

Slide 45
Intrinsic Muscles of Tongue

Transverse section (upper)

1. Dorsum of the tongue (1, 2 &3)
4. Transverse muscle
5. Septum of tongue
6. Vertical muscles
7. Inferior longitudinal muscles
8. Genioglossus muscle

Longitudinal section (Lower)

3. Dorsum of the tongue
4. Inferior surface
5. Transverse muscle
6. Inferior longitudinal muscle

Slide 46
Filliform (upper) and Fungiform Papillae

1. Filliform papilla
2. Fungiform papilla
3. Secondary CTs papillae

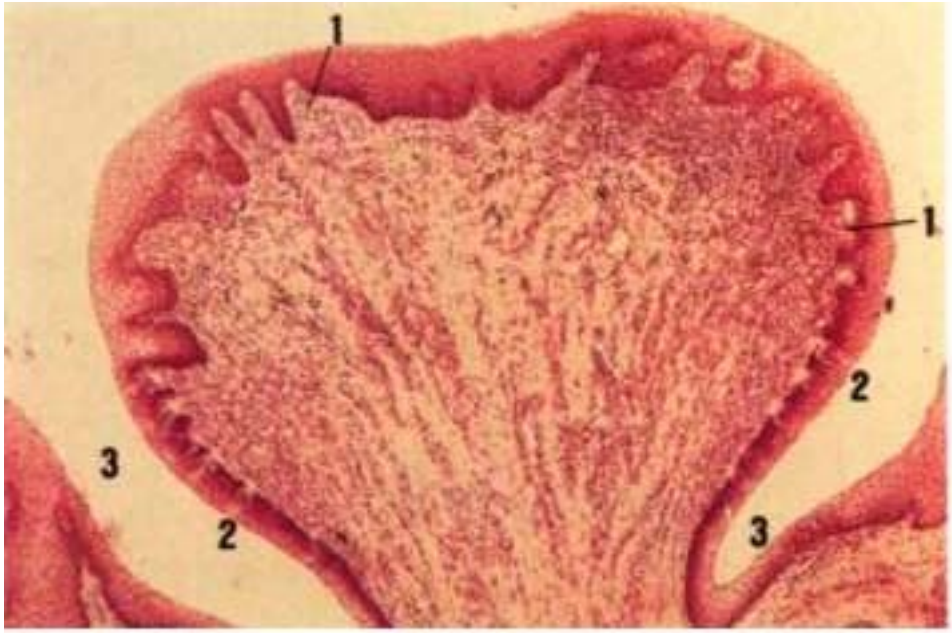

Slide 47
Circumvallate (upper) and Folliate (lower) Papillae

Circumvallate papilla

1. Secondary CTs papilla
2. Taste buds
3. Trough or farrow

Folliate papillae

1. Foliate papilla
2. Taste bud
3. Von Ebner gland
4. Excretory duct of the gland

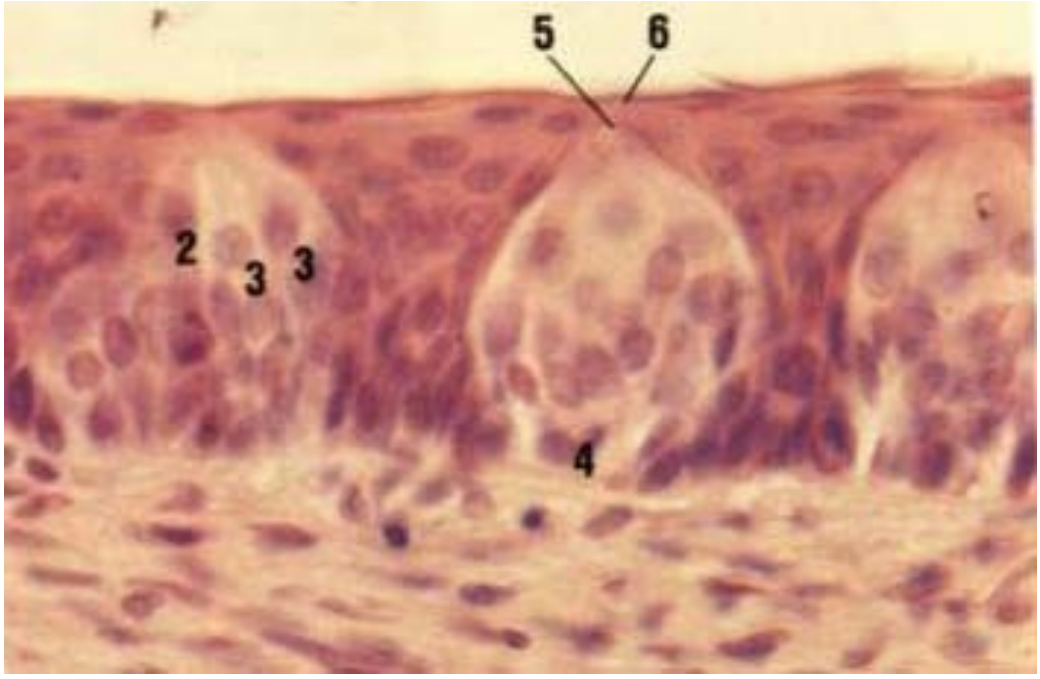

Slide 48 Taste bud

1. Taste cell,
2. Supporting cells
3. Basal cells
4. Taste canal
5. Taste bore

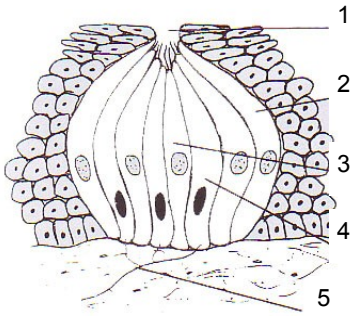

Diagram XXIX Taste Bud

1. Taste bore
2. Outer supporting cells
3. Inner supporting cells
4. Neuro-epithelial cells
5. Nerve fibers

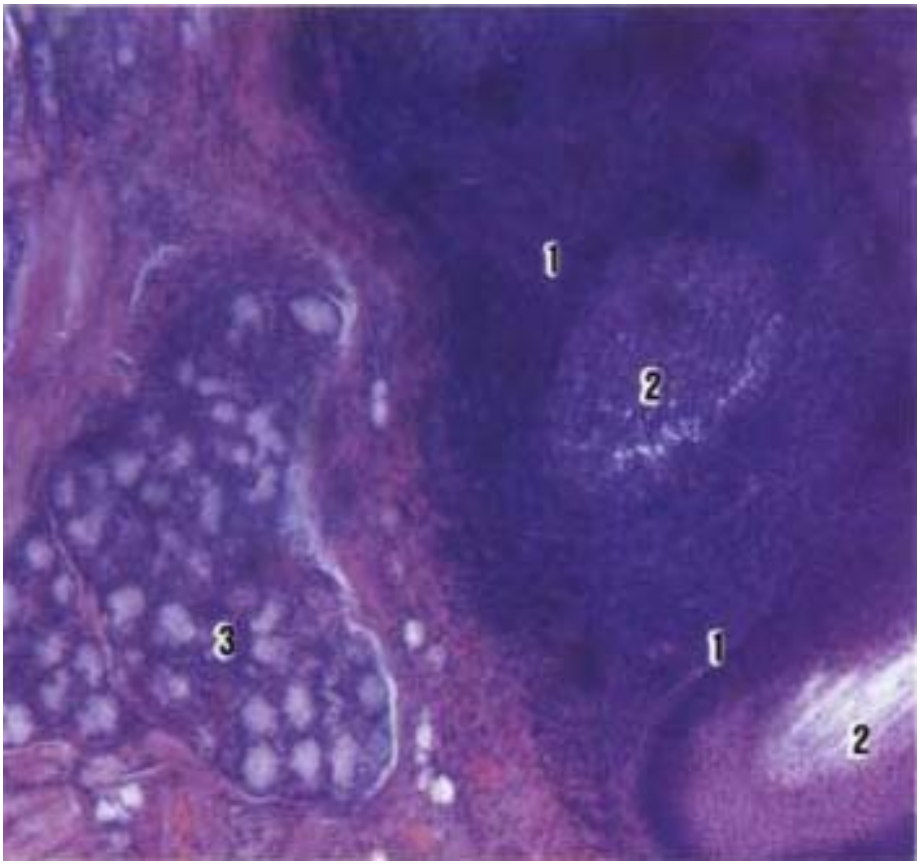

Slide 49
Posterior 1/3 of Tongue

1. Lingual lymphatic follicle
2. Germinal center
3. Mucous glands

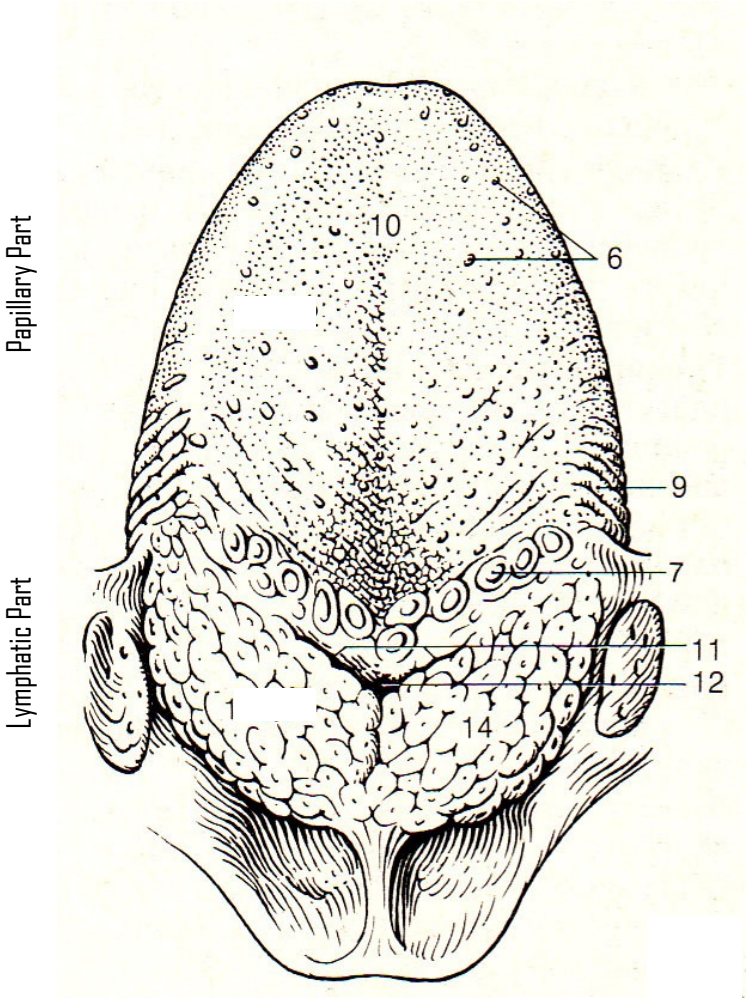

Diagram XXVII
Dorsum of the Tongue

6. Fungiform papillae
7. Circumvallate papillae
8. Folliate papillae
9. Median sulcus
10. Sulcus terminalis
11. Foramen cecum, a depression at the apex of the terminal sulcus represent developmental remnants of thyroglossal duct.

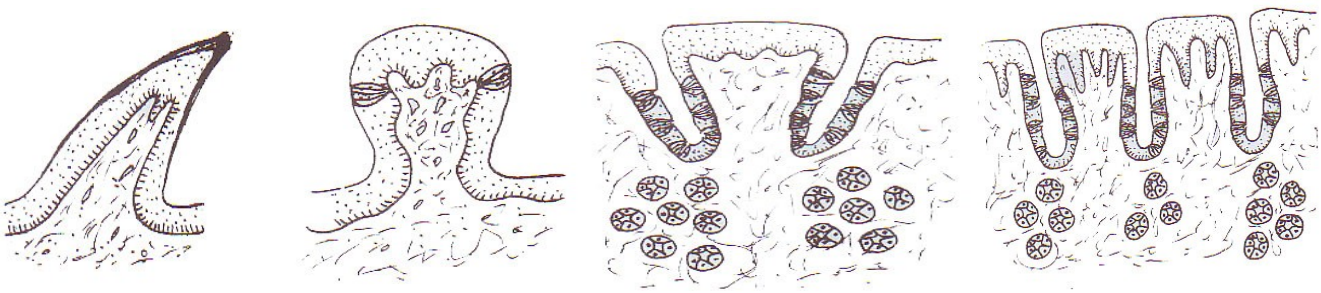

Filliform Papilla | Fungiform Papilla | Circumvallate Papilla | Folliate Papilla

Diagram XXVIII. Papillae of the Tongue

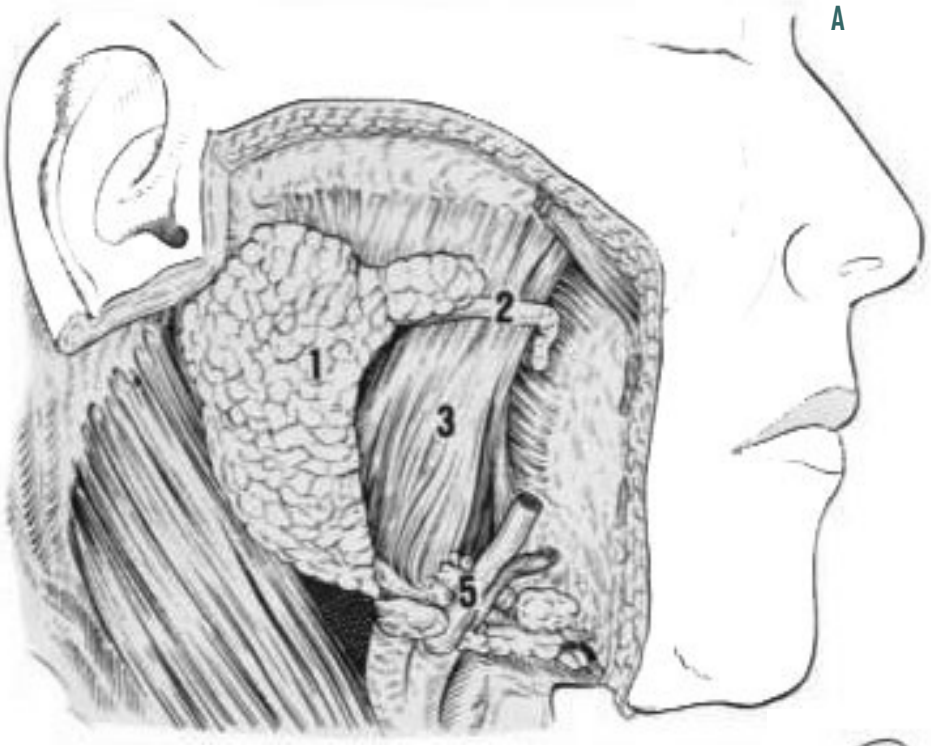

SALIVARY GLANDS

See legend on page 59

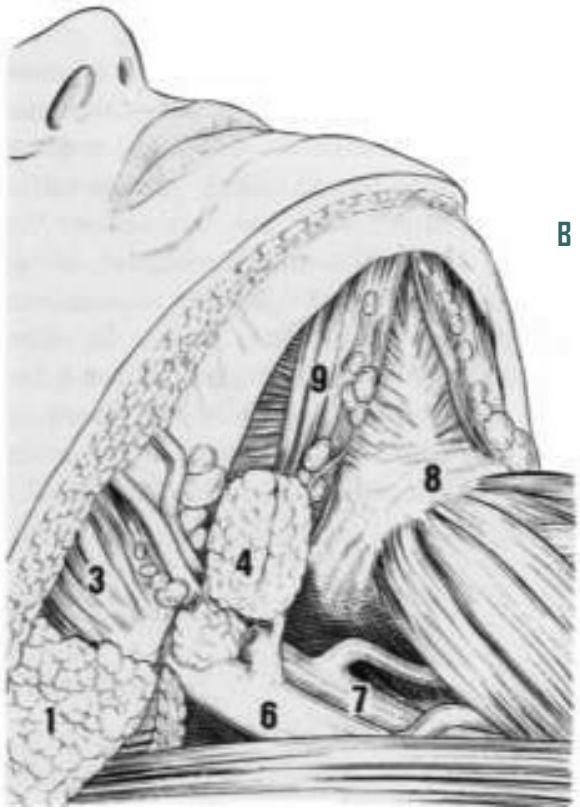

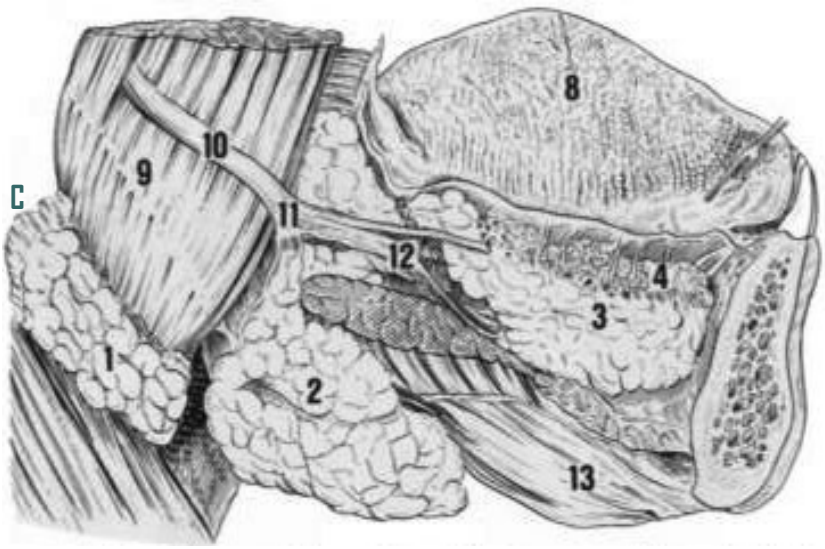

D

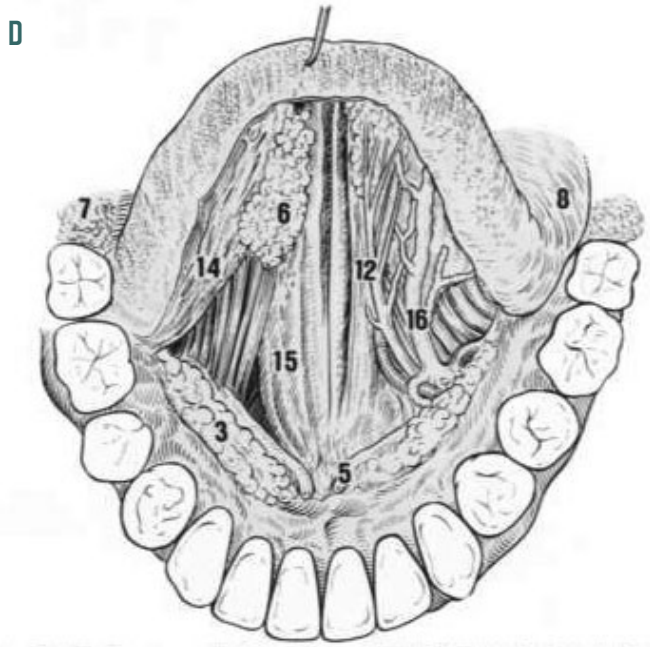

E

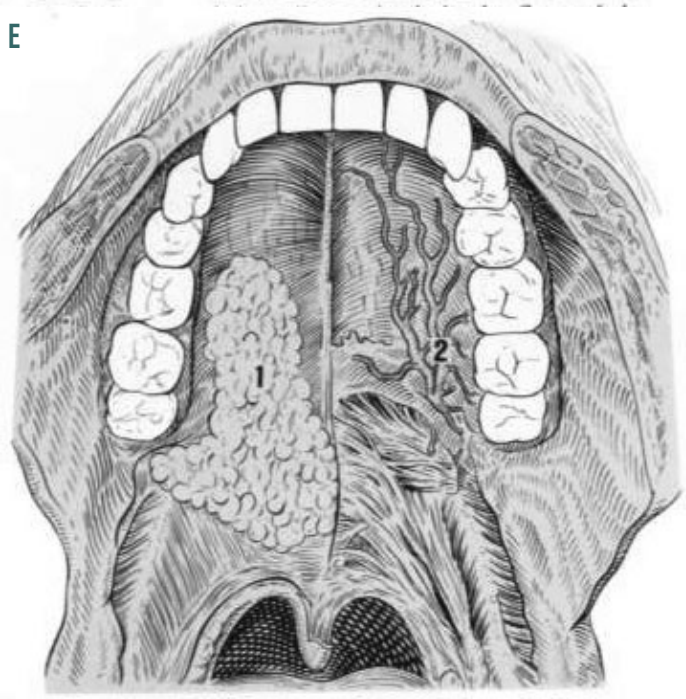

G

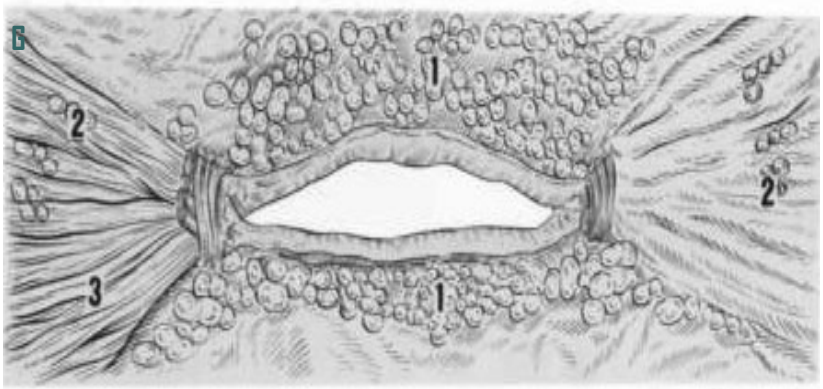

Diagram XXXI
Parotid, Submandibular and Sub-lingual Salivary Glands

A & B

1. Parotid gland
2. Stenson's duct
3. Masseter muscle
4. Submandibular gland
5. Facial vein
6. Internal jugular vein
7. External carotid artery
8. Hyoid bone
9. Digastrics muscle (anterior belly)

C & D

1. Parotid gland
2. Submandibular gland
3. Sublingual gland
4. Sublingual gland duct
5. Warton's duct
6. Anterior lingual gland
7. Retromolar gland
8. Tongue
9. Masseter muscle
10. Lingual nerve
11. Submandibular ganglion
12. Hypoglossal nerve
13. Digastrics muscle (anterior belly)
14. Styloglossus muscle
15. Genioglossus muscle
16. Lingual nerve

E. Palatine glands

1. Palatine glands
2. Greater palatine artery

G. Labial & Buccal Gs

1. Labial glands
2. Buccal glands
3. Buccinators M

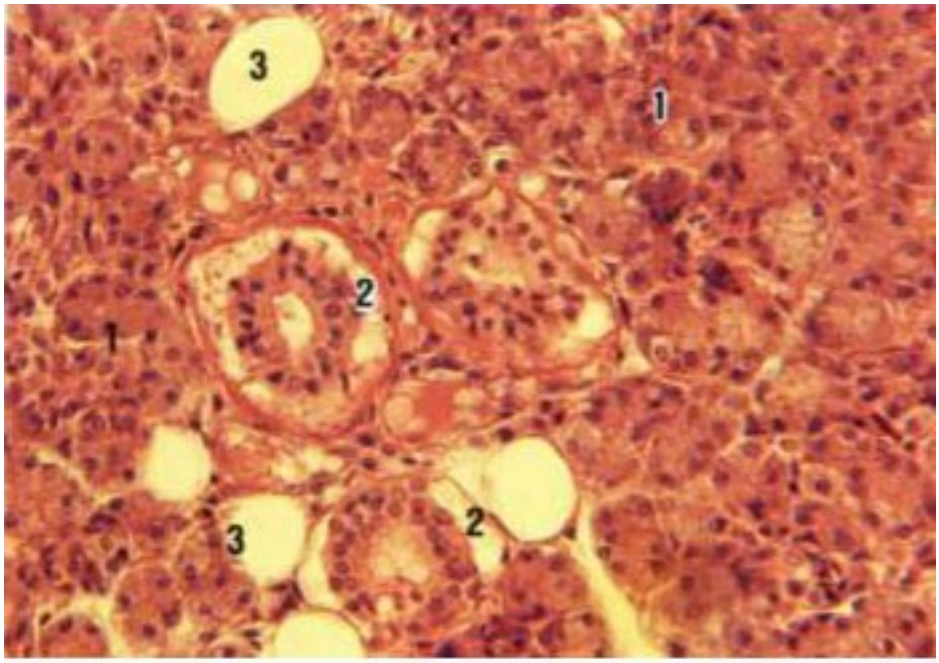

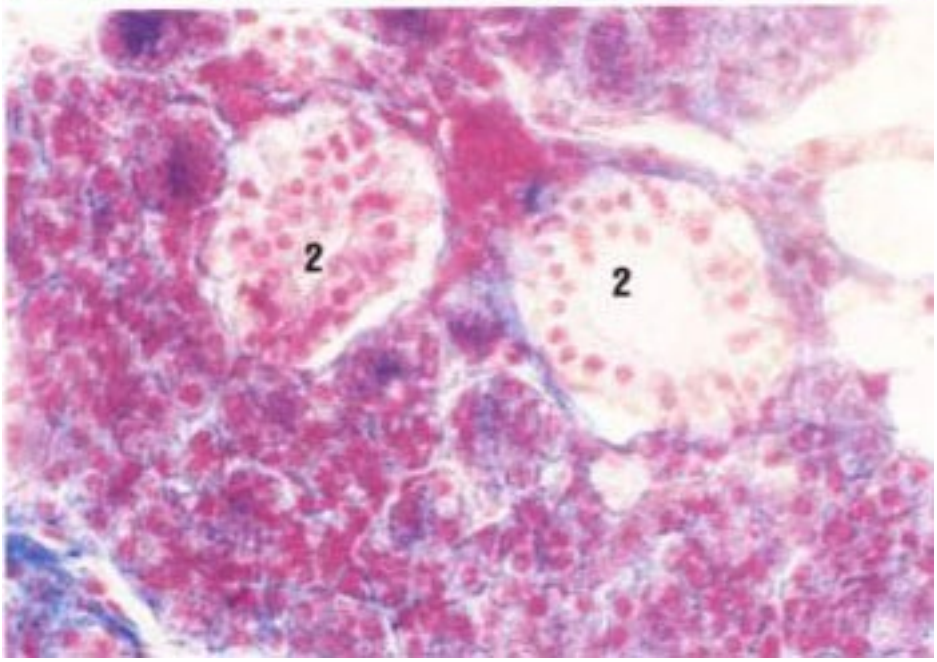

Slide 50
Parotid Gland

1. Serous or seromucous alveoli
2. Striated duct
3. Adipose cell

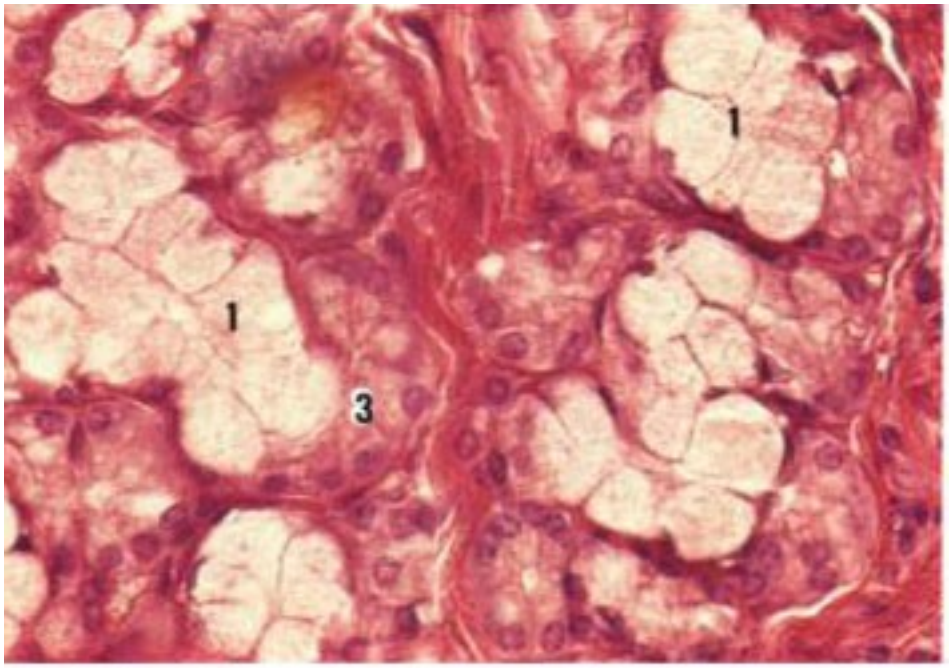

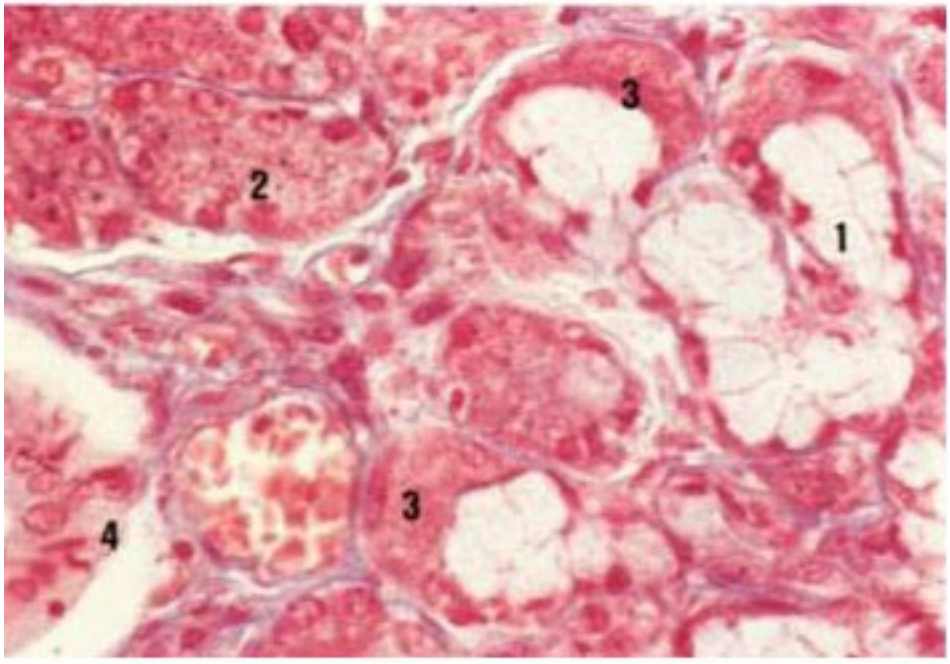

Slide 51
Submandibular Gland

1. Mucous cell
2. Mixed alveolus
3. Serous alveolus
4. Striated duct

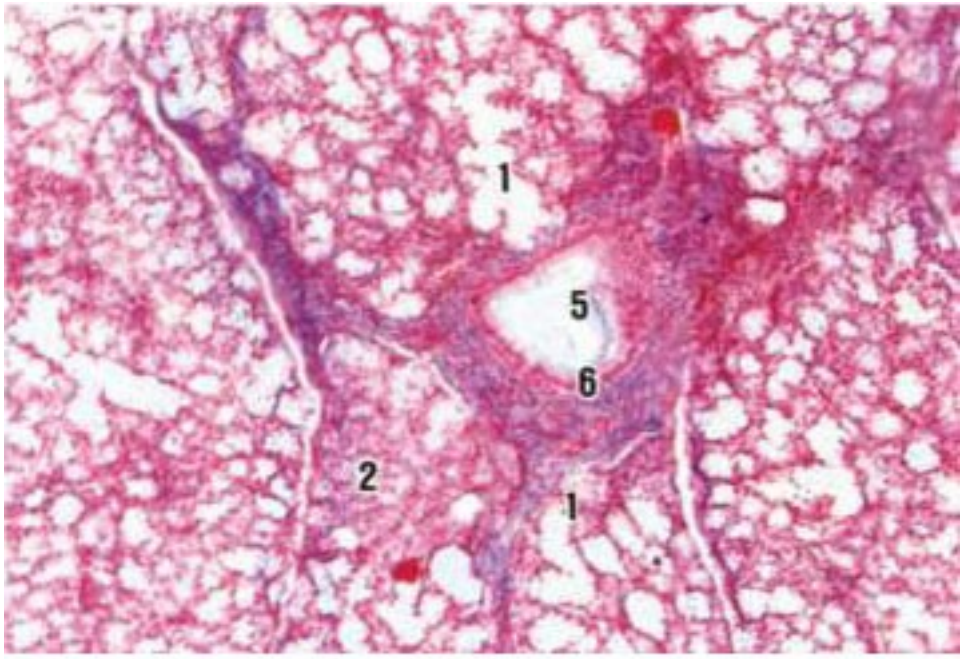

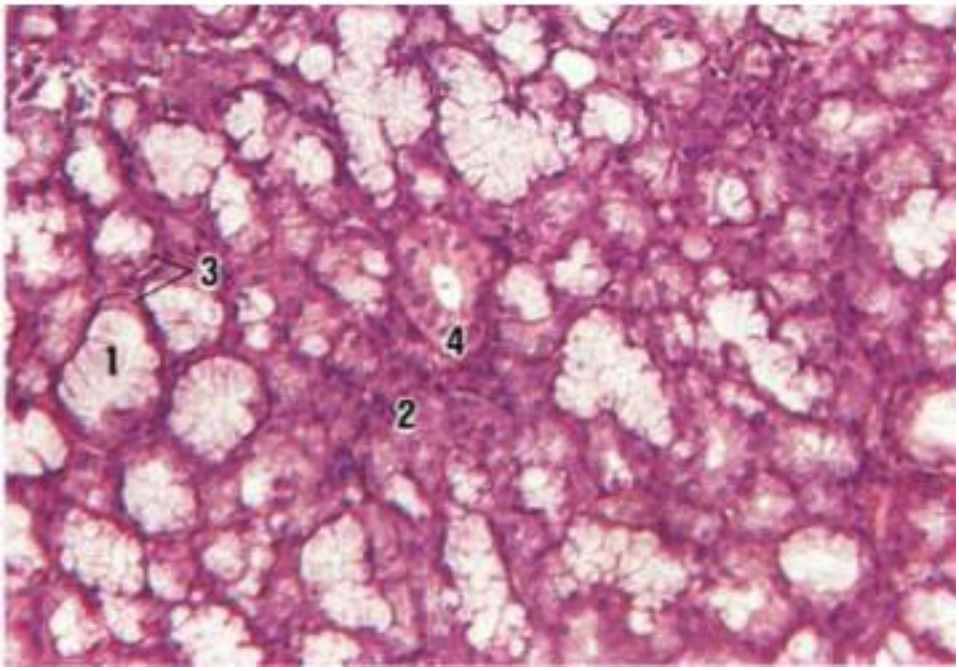

Slide 52
Sublingual Gland

1. Mucous alveolus
2. Serous alveolus
3. Serous demilune
4. Striated duct
5. Interlobular excretory duct
6. Interlobular connective tissue septa

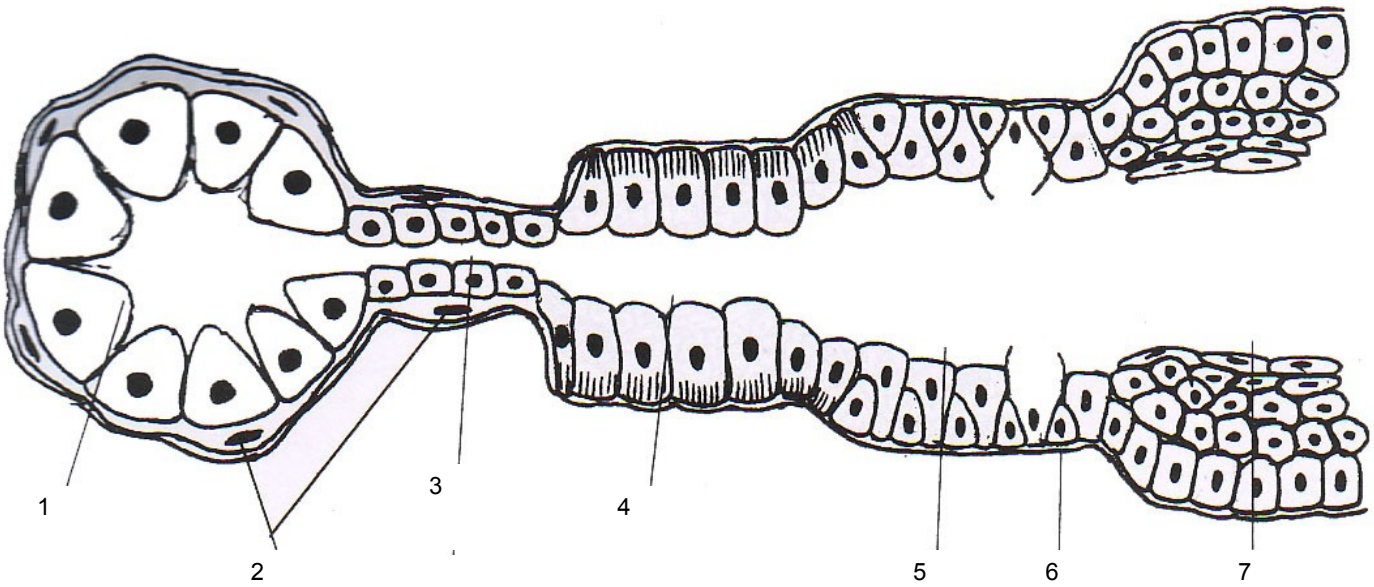

Diagram XXXII
Parenchymal Elements of Salivary Glands

1. Serous acinus
2. Myoepithelial cells
3. Intercalated duct
4. Striated duct
5. Excretory duct
6. Basal lamina
7. Main duct

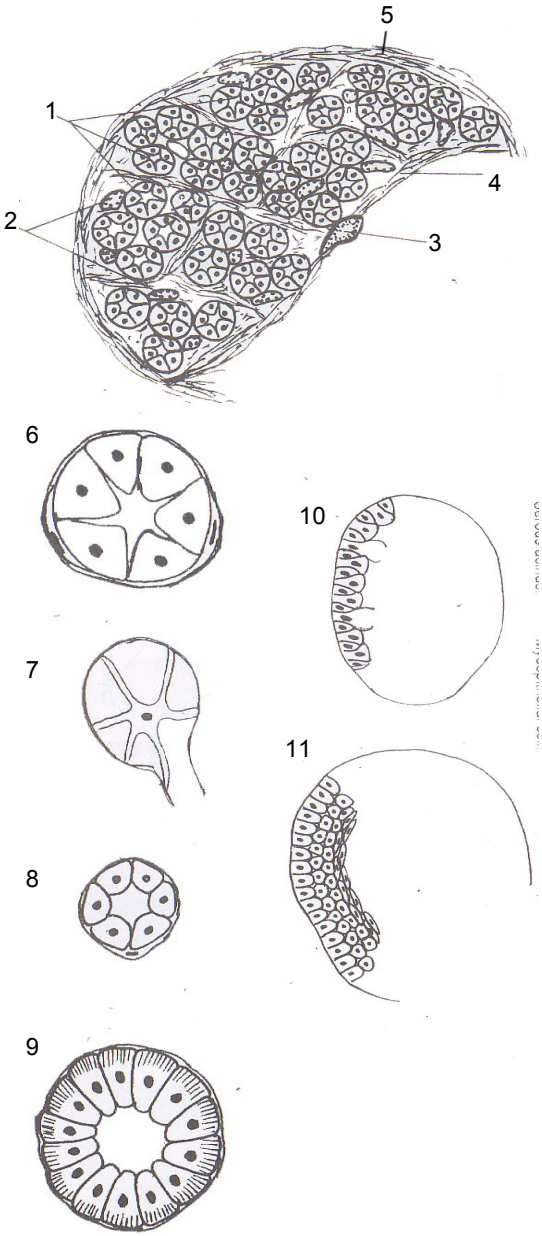

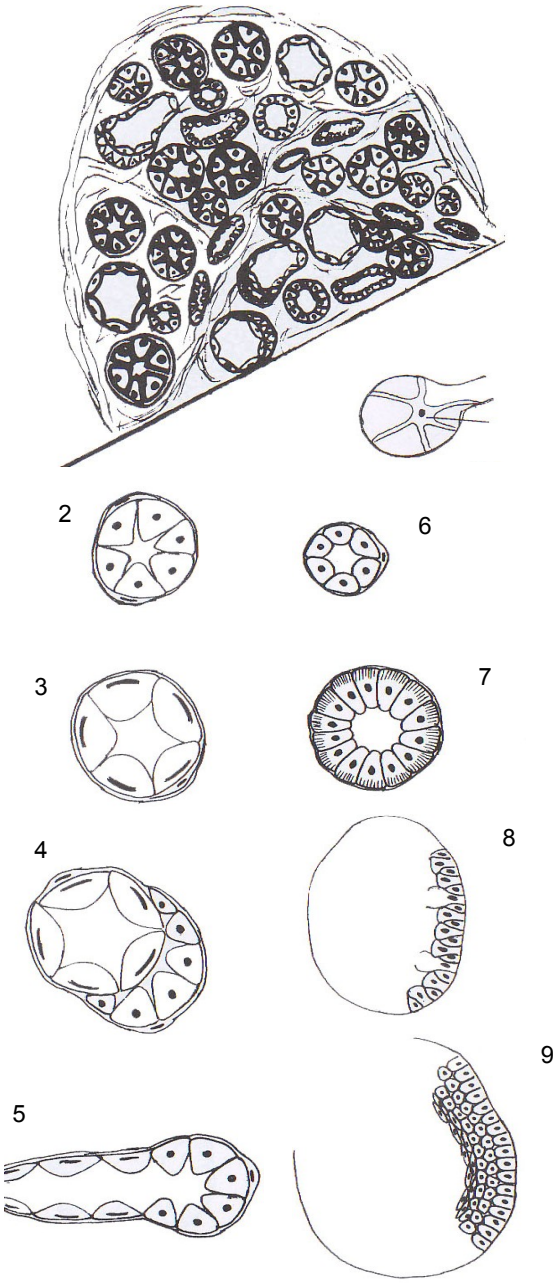

Diagram XXXIII
Histological Section in:
Parotid Salivary Glands (Left)

1. Serous acini
2. Interlobular ducts
3. Excretory ducts
4. Connective tissues septa
5. Serous acini
6. Myoepithelial cell
7. Intercalated duct
8. Striated duct
9. Excretory duct
10. Main duct

Submandibular Salivary Gland (Right)

1. Meoepithelial cell
2. Serous acinus
3. Mucous acinus
4. Demlune of von Ebner
5. Tubuloalveolar form
6. Intercalated duct
7. Striated duct
8. Excretory duct
9. Main duct

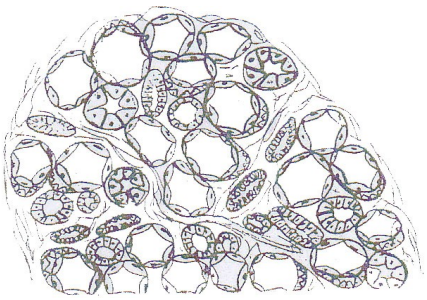

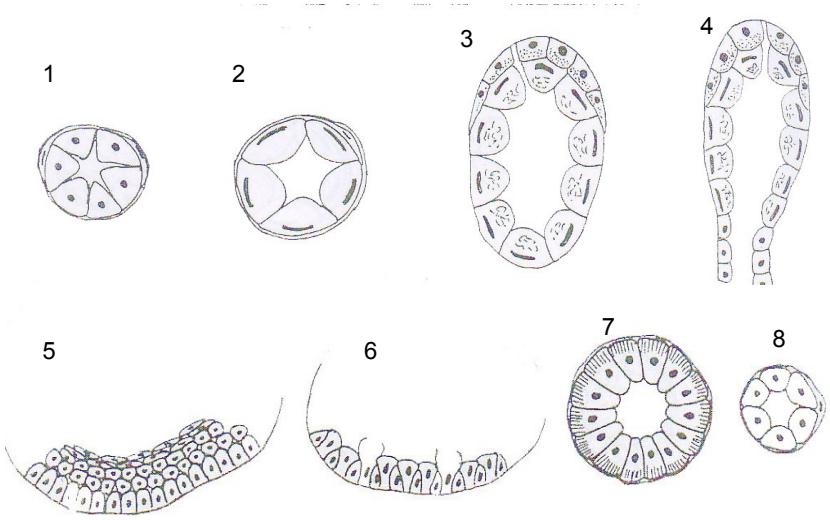

Diagram XXXIV
Histological Section in Submandibular Salivary Gland

1. Serous acinus
2. Mucous acinus
3. Demilune of von Ebner
4. Tubuloalveolar form
5. Main duct
6. Excretory duct
7. Striated duct
8. Intercalated duct

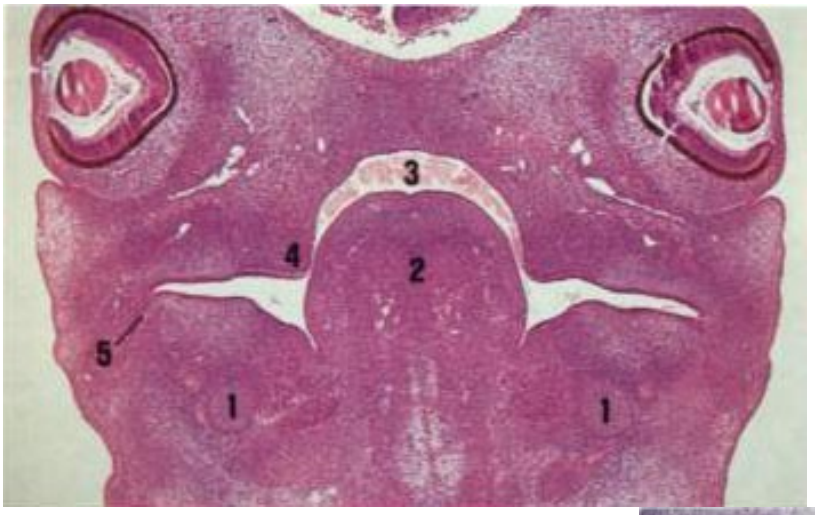

DEVELOPMENT OF MANDIBLE & MAXILLA

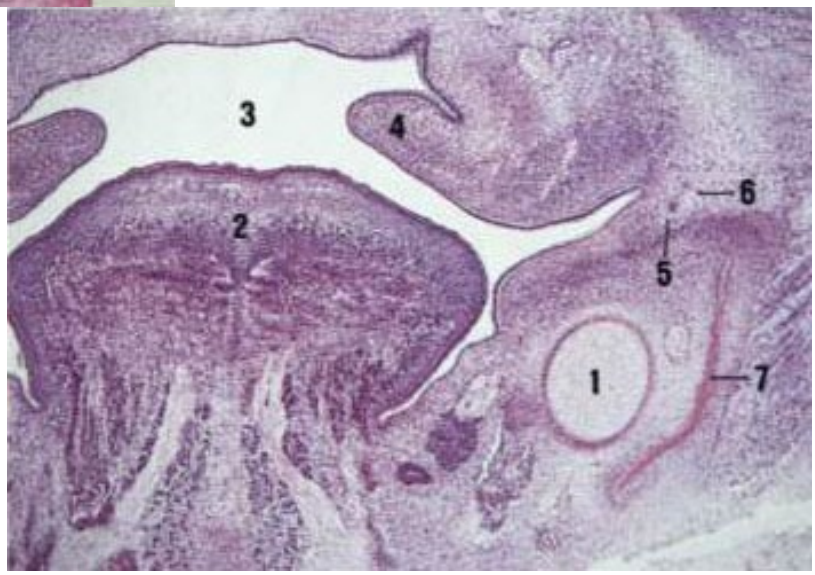

Slide 53

Upper

Frontal section of the middle part of the primitive oral cavity of a 37-day human embryo (H&E X30)

1. Meckel's cartilage
2. Tongue
3. Stomodeum
4. Lateral palatine process
5. Chivitz's organ

Lower

Frontal section of the middle part of primitive oral cavity of 45-day human embryo (H&EX)

1. Meckel's cartilage
2. Tongue
3. Stomodeum
4. Lateral palatine process
5. Chievitz's organ
6. Buccal nerve
7. Mandibular bone

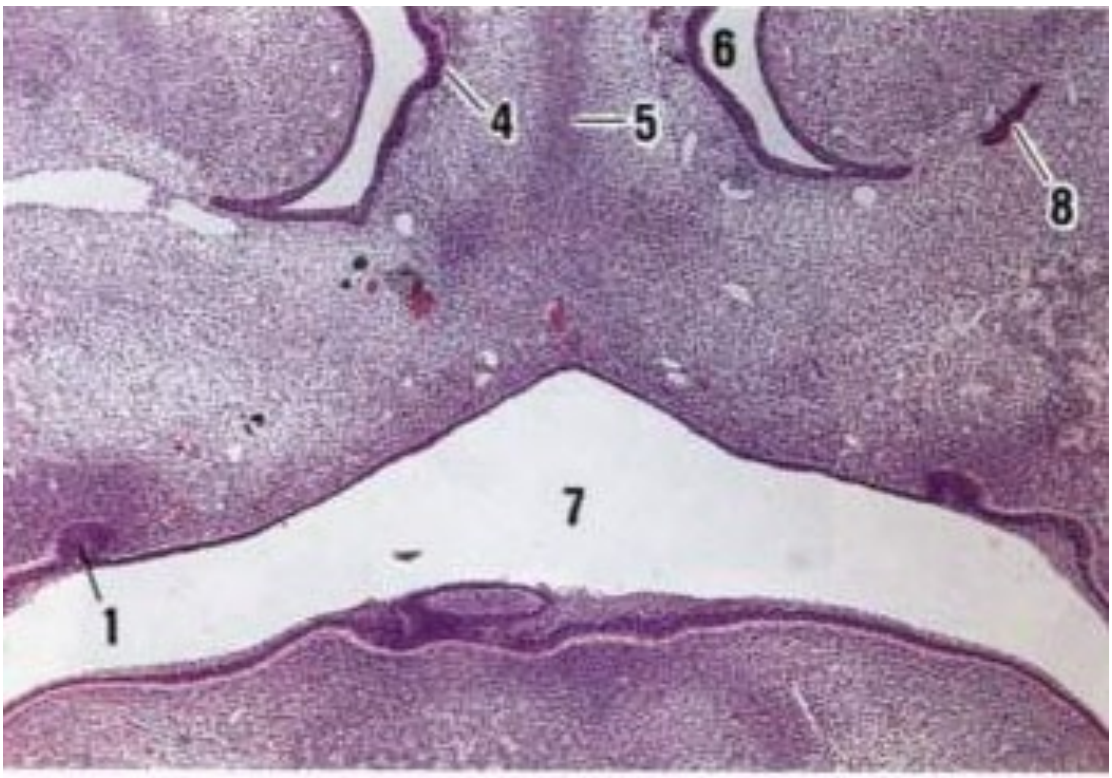

Slide 54

Frontal section of the development of tooth germ of a 41-day human embryo (left) and a hiegher magnification showing developing tooth in the bud stage (H&E-X20 – X600)

1. Tooth bud of primary lateral incisor
2. Oral epithelium
3. Lamina properia (mesenchymal connective tissue)
4. Primordium of vomernasal organ
5. Primitive septal cartilage
6. Nasal cavity
7. Oral cavity
8. Primordium of nasolacrimal duct

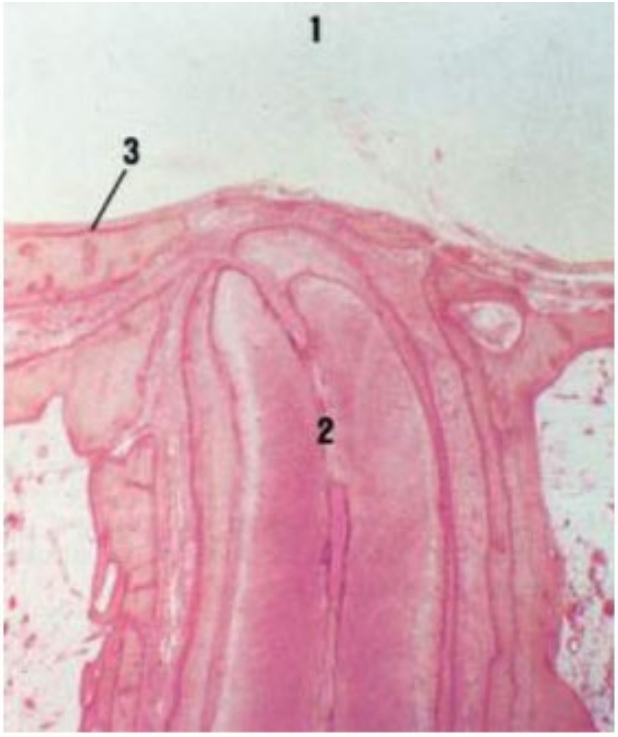

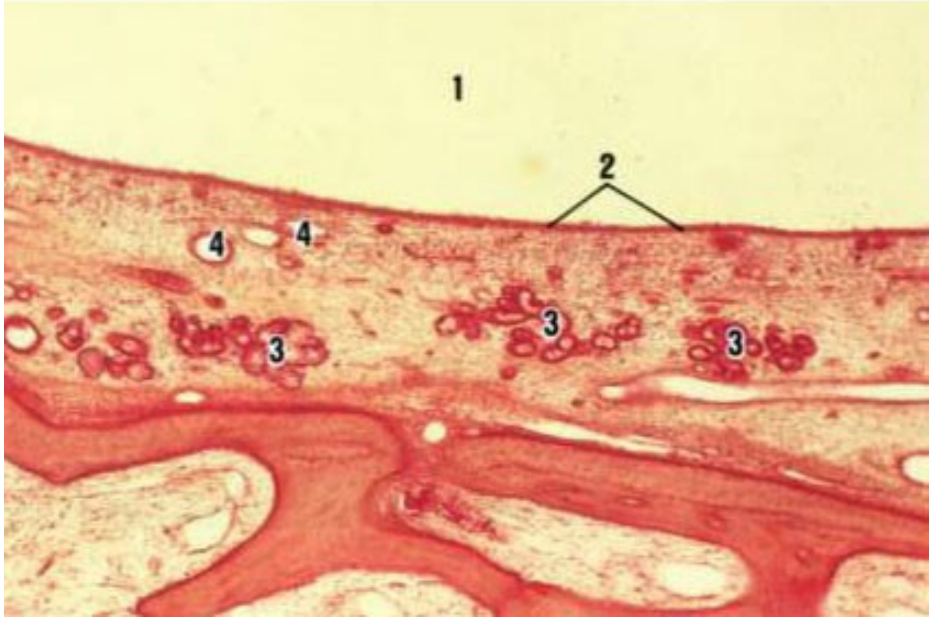

MAXILLARY SINUS

Slide 55
Relation of Root Apex (upper) - Sinus Mucosal Lining (lower)

Upper

1. Maxillary sinus
2. Root apex of maxillary molar
3. Sinus mucosal lining

Lower

1. Maxillary sinus
2. Ciliated pesudostratified columnar epithelium of sinus
3. Seromucous glands
4. Excretory ducts of seromucous glands

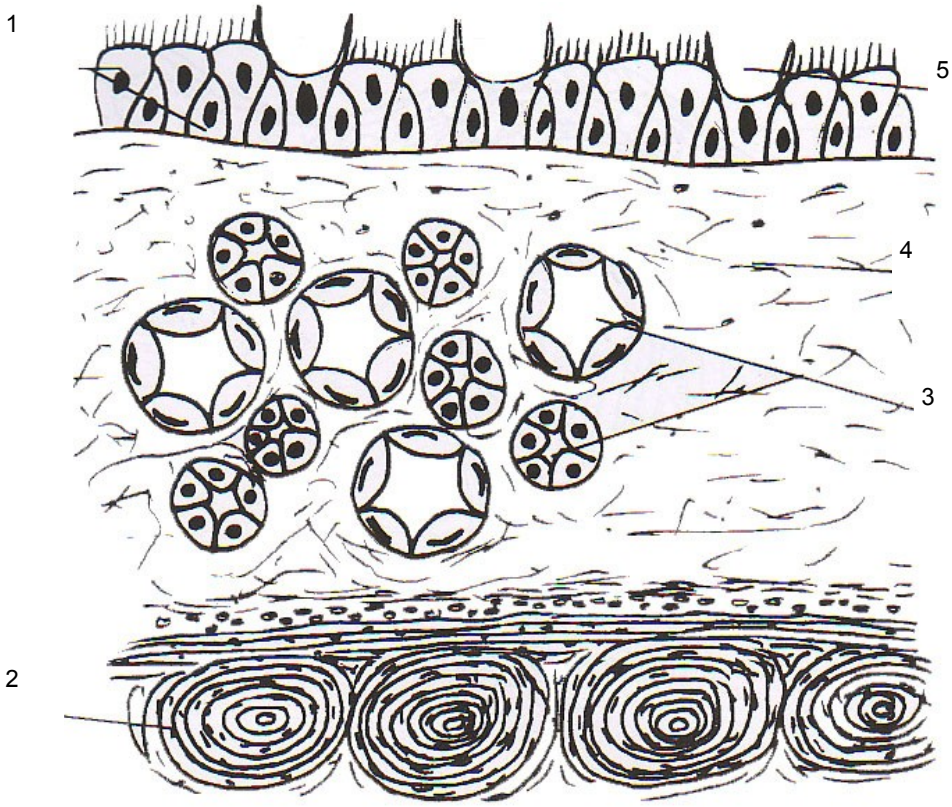

Diagram XXXV
Lining of Maxillary Sinus

1. Pesudostratified columnar epithelium
2. Bone
3. Mixed gland
4. Lamina properia
5. Gpblet cells

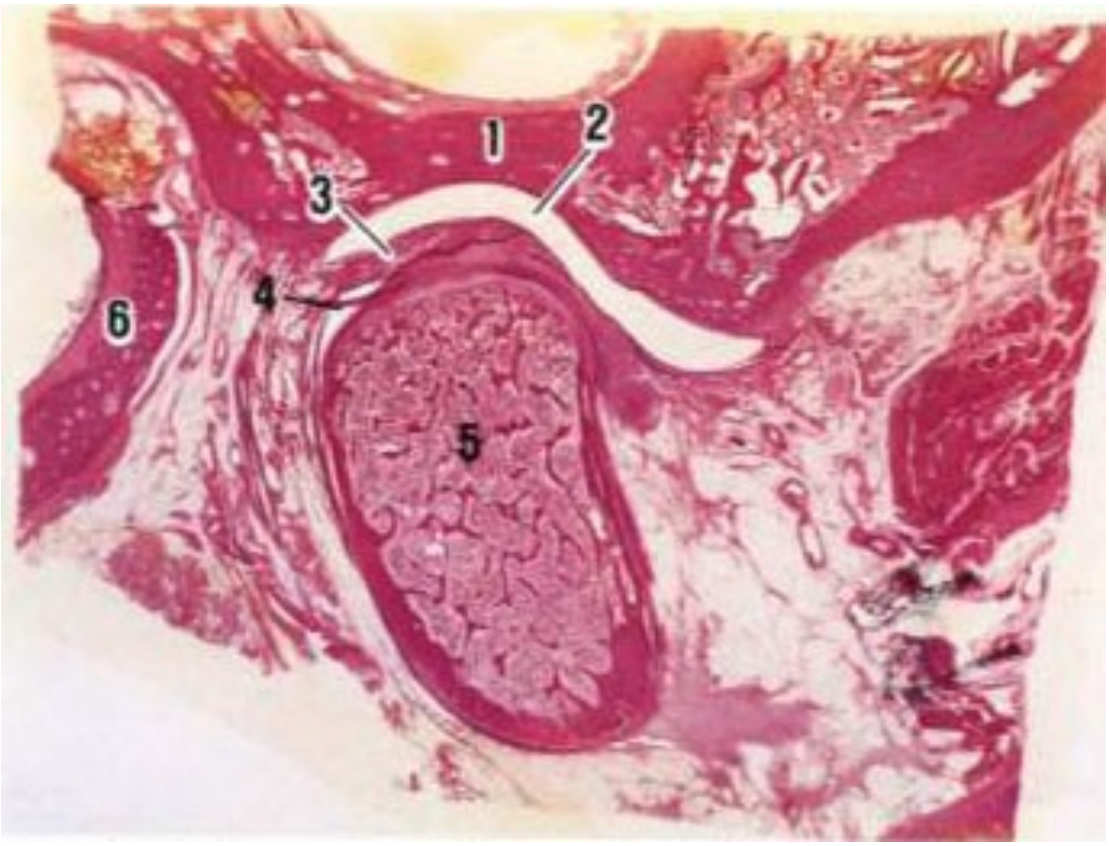

TEMPOROMANDIBULAR JOINT

Slide 56

Temporo-Mandibular Joint (Sagittal Section)

1. Glenoid fossa
2. Superior (tempero-discal) synovial cavity
3. Articular disc
4. Inferior (condro-discal) synovial cavity
5. Condylar head
6. Mastoid process

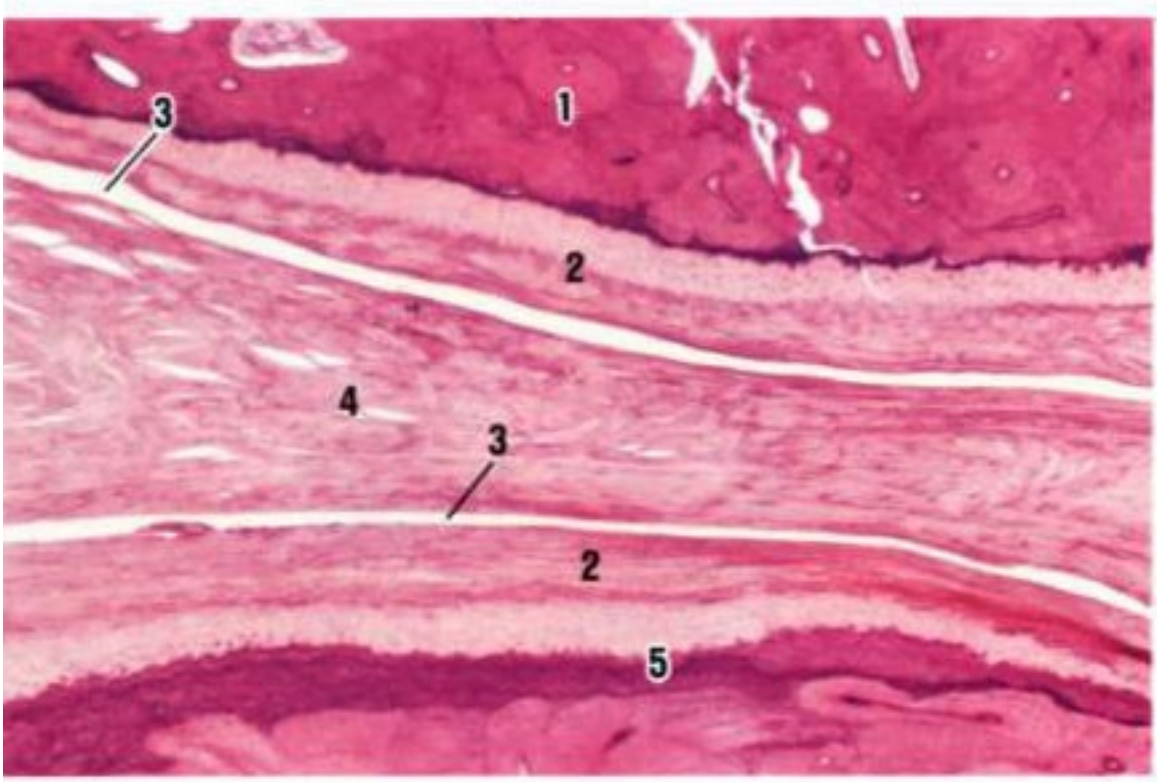

Slide 57
Articular Disc

1. Glenoid fossa
2. Fibrous covering of temporal bone
3. Inferior synovial cavity
4. Articular disc
5. Head of mandibular condyle

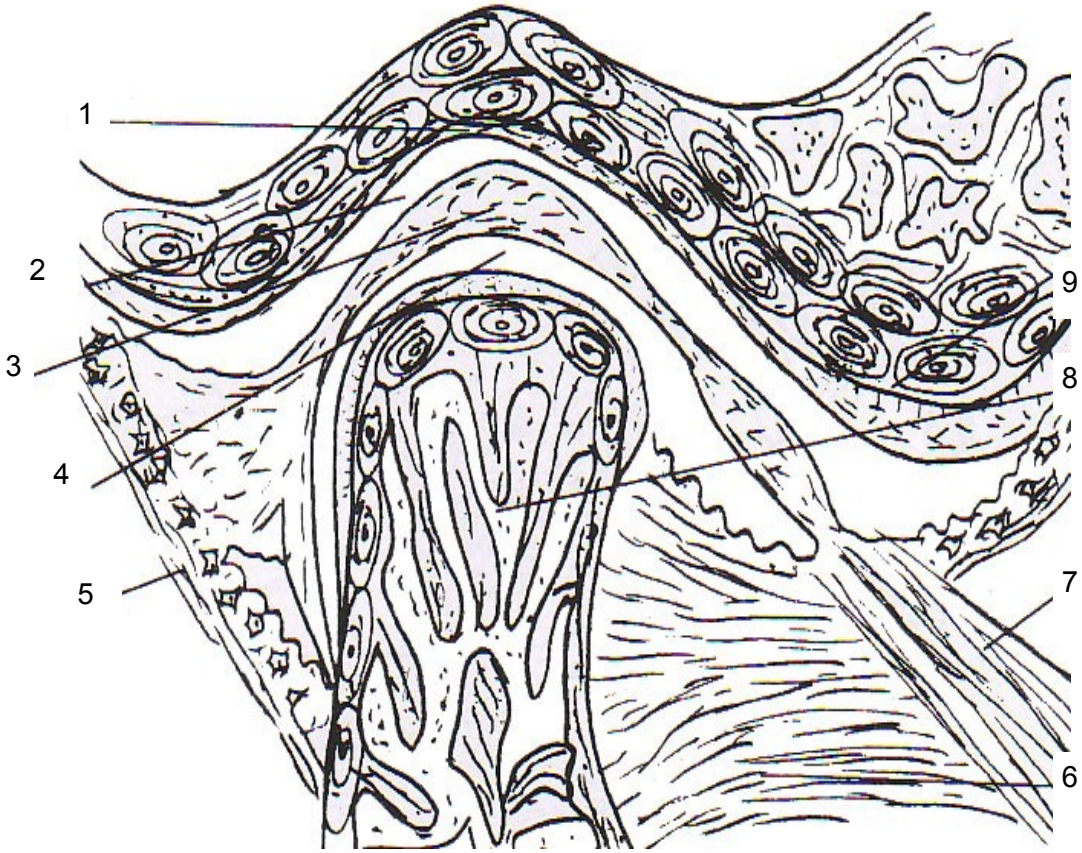

Diagram XXXVI
Histology of TMJ

1. Articular fossa
2. Upper joint cavity
3. Articular disc
4. Lower joint cavity
5. Articular capsule
6. Inferior head of lateral pterygoid muscle
7. Superior head of lateral pterygoid muscle
8. Condyle
9. Articular eminence